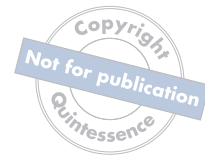



COMPOSITE VENEERS: THE DIRECT-INDIRECT TECHNIQUE



Library of Congress Cataloging-in-Publication Data

Names: Fahl, Newton, Jr., author. | Ritter, André V., author.

Title: Composite veneers : the direct-indirect technique / Newton Fahl, Jr. and André V. Ritter.

Description: Batavia, IL : Quintessence Publishing Co, Inc, [2020] | Includes bibliographical references and index. | Summary: "The book discusses the many applications of the direct-indirect technique using composites, including prepless contact lenses and veneers, veneers with preparation (discolored teeth), fragments, diastema closure, and noncarious cervical lesions, and offers step-by-step protocols for each"-- Provided by publisher.

Identifiers: LCCN 2019046871 | ISBN 9780867159592 (hardcover)

Subjects: MESH: Dental Veneers | Composite Resins--therapeutic use | Dental

Restoration, Permanent--methods | Esthetics, Dental | Contact Lenses

Classification: LCC RK652.5 | NLM WU 515 | DDC 617.6/95--dc23

LC record available at <https://lccn.loc.gov/2019046871>



© 2020 Quintessence Publishing Co, Inc

Quintessence Publishing Co, Inc

411 N Raddant Road

Batavia, IL 60510

www.quintpub.com

5 4 3 2 1

All rights reserved. This book or any part thereof may not be reproduced, stored in a retrieval system, or transmitted in any form or by any means, electronic, mechanical, photocopying, or otherwise, without prior written permission of the publisher.

Editor: Leah Huffman

Design: Sue Zubek

Production: Angelina Schmelter

Printed in Brazil



COMPOSITE VENEERS

THE DIRECT-INDIRECT
TECHNIQUE

Newton Fahl, Jr, DDS, MS

Director, Fahl Center
Private Practice
Curitiba, Brazil

André V. Ritter, DDS, MS, MBA, PhD

Professor and Chair
Department of Cariology and Comprehensive Care
New York University College of Dentistry
New York, New York



QUINTESSENCE PUBLISHING

Berlin | Chicago | Tokyo
Barcelona | London | Milan | Mexico City | Moscow | Paris | Prague | Seoul | Warsaw
Beijing | Istanbul | Sao Paulo | Zagreb



Dedication

***For from Him and through Him and for Him are all things.
To Him be the glory forever! Amen.***

Romans 11:36

To “Vida” Grace, my loving wife and best friend. Thanks for always giving me the courage and push to take off and supporting me with the fuel to fly high. —NF

I dedicate this book to my father, Nestor M. Ritter (1941–2017), without whom none of this would have been possible. —AVR

Acknowledgments

I want to express my deepest love and gratitude to my parents—my role models in life—and my mentor and friend, Jerry Denehy. I’m deeply indebted to Mariano Flores (in memoriam) and Ron Jackson for opening up doors. A very special thanks to the Fahl Center Team for their dedication and support throughout my professional career. I am grateful to all educators, peers, and friends who have left their imprint on my personal and professional life. —NF

I would like to thank those who directly or indirectly contributed to my professional development. A very special thank you to my wife and partner in life, Jane Pozza, for her patience and support during the preparation of this book. —AVR

Contents

	Foreword	<i>vi</i>
	Preface	<i>vii</i>
1	The Direct-Indirect Concept	1
2	Composite Resins and Layering Strategies	19
3	Prepress Contact Lenses and Veneers	43
4	Veneers with Preparation: Discolored Teeth	127
5	Indirect Restorations Fabricated on Flexible Silicone Models	191
6	Direct-Indirect Class V Inlays	249
	Index	284

Foreword

Direct composite resin restorations currently provide long-term, affordable esthetics when utilized in the hands of a skilled and knowledgeable clinician. Indirect restorations also certainly provide excellent esthetics with distinct advantages and disadvantages compared to direct restorations. This book covers the concept of combining both approaches into a direct-indirect procedure with composite resin, a technique unfamiliar to many dental practitioners. The direct-indirect procedure allows the practitioner the opportunity to utilize the knowledge and skill of direct resin placement with the precision and convenience of indirect finishing and cementation.

I am very pleased that Drs Newton Fahl and André Ritter have chosen to write the first textbook that presents the unique combination of these procedures. Both authors bring years of recognized excellence in practice and a wealth of knowledge and experience with composite resin systems, as well as the respect of clinicians worldwide. Although perhaps best known for his effective clinical abilities, lecturing, and demonstration skills with direct composite resin restorations, Dr Fahl has utilized the direct-indirect restoration technique for many years with great success in his practice.

With excellent photography, precise drawings, and descriptive text, this book demonstrates the range of procedures that may be successfully treated with the direct-indirect technique. It also clearly defines the sequential steps necessary for their implementation. In describing these steps, the book provides an invaluable source of information for the construction of the direct restoration, the intraoral and extraoral finishing of the indirect restoration, and the proper selection of bonding and luting agents. For the reader, this is like getting two books in one, tapping into all of the authors' knowledge in both direct and indirect areas. The authors share their recommendations on the proper selection and manipulation of resins and the correct choice and use of opacities for blocking stains. Bonding agents and luting agents and their involved procedures are also outlined in detail. An up-to-date review of currently available materials is described along with the specific techniques to properly utilize each of them effectively, and the clinical cases are clearly illustrated through step-by-step sequences.

As a clinician-educator myself who has worked with composite resins for over 50 years, I find this book to be an essential read for all dental practitioners who use composite resin systems. The direct-indirect technique offers great promise, but the wealth of information present in this book will be extremely valuable to anyone no matter whether they use direct, indirect, or direct-indirect techniques. This is a book well worth the wait!

Gerald E. Denehy, DDS, MS

Emeritus Professor

Department of Operative Dentistry

University of Iowa College of Dentistry

Preface

It is our innermost wish that this book becomes more than just another book on one's shelf. We want the reader to be adventurous in trying out a technique that has made a tremendous impact on the lives of so many, including patients, students, and our own lives above all. As with all that is new, learning the direct-indirect technique will require dedication and a strong willingness of the reader to be better. Once you master the lessons contained in this book, you will never view composite resins the same way ever again. We wish you a great reading and learning adventure!

It has been over 25 years since I came across Nathan Birnbaum's publication on what I later came to call *direct-indirect restorations*. His work motivated me to investigate new ways to use composite resins other than the conventional direct approach. At first, the technique was very empirical, lacking a clinical protocol that would minimize failures. So I started experimenting with ways of working faster and more predictably to achieve outstanding results. My initial trials involved restoring simple cases with a single shade to primarily correct minor morphologic discrepancies. Soon I realized the direct-indirect technique could be expanded to other clinical challenges to address form and color issues of the esthetically compromised dentition. Thus I ventured into an arena that would reveal itself a lot more encompassing than I had ever fathomed. I moved from single-shaded contact lenses to thicker, more complex veneer-type restorations. Gradually, the level of complexity of what I could do with the direct-indirect approach became so intricate that it required being methodized into logical fundamental guidelines and clinical protocols to assist anyone who wanted to learn this unknown concept. Over the years, as my clinical expertise became intermingled with my teaching of the technique, ideas, workflows, and step-by-step protocols started to come together logically. It is precisely this long-term assembly of trials and errors, successes, and failures that I am pleased to introduce in this work with my coauthor, Dr André Ritter. Dr Ritter's expertise in clinical dentistry and research, along with his outstanding editorial knowledge, was paramount for the compilation and completion of this book in its present form.

Our goal is to take the reader on a pleasurable journey to learn the direct-indirect technique. We divided the book into six distinct yet confluent chapters. The first chapter presents the rationale and introduces the benefits of the method. Chapter 2 lays the foundation for the proper selection of the restorative materials—composites, tints, and opaques—and discusses layering concepts and their clinical implications. Chapter 3 introduces prepless contact lenses and veneers based on minimally invasive restorative strategies to solve minor to moderate anatomical problems. In chapter 4, solving discolored substrate challenges is addressed, introducing preparation design and more elaborate layering protocols with the use of opaques. Multiple contact lenses and veneers—a challenging clinical scenario—is presented in chapter 5 as an indirect option on flexible models to assist the clinician in optimizing results. Finally, chapter 6 discusses and teaches the restoration of noncarious cervical lesions via Class V inlays, a technique that assembles all the benefits of the direct-indirect protocol to help the clinician address a prevalent pathology of this era with great success.



The Direct-Indirect Concept

Use of Composite Resins

Light-activated composite resins are used extensively for the conservative functional restoration and esthetic enhancement of both anterior and posterior teeth. Modern composite resins present excellent esthetic and physical properties, are relatively easy to use for an array of simple and complex applications, do not require sophisticated and off-site equipment for their fabrication, and offer a comparatively inexpensive treatment option for patients of all ages. Through considerable investment in research and innovation, dental manufacturers have developed composite resins that can mimic with high fidelity the optical and colorimetric characteristics of dentin and enamel.^{1,2} At a time when digital dentistry is growing by the minute and CAD/CAM technology seems to permeate the clinical and laboratory environments irreversibly, there is still a huge demand for the use of minimally invasive adhesive protocols through the methodical and conscious application of composite resins. For decades the continuous evolution of adhesive technologies has generated the development of several noninvasive esthetic techniques using composite resins to correct a variety of defects in the color and shape of the anterior dentition. These defects include tetracycline staining, fluorosis, hypoplasia, hypocalcification, aging, pulpal necrosis, and morphologic defects due to caries, trauma, and genetic factors.³⁻⁹ Although far from being ideal, current adhesive systems offer an extremely broad and safe restorative potential, requiring only ultraconservative preparation or even no preparation of the dental structure, providing restorations with integrity and longevity.

When compared with ceramic restorations, the clinical longevity of composite resins seems to be a critical factor in the choice of restorative material for both clinicians and patients (Table 1). Although there are overlaps in their clinical indications, it is necessary to consider that composite resins and ceramics are distinct materials in their physical and mechanical properties and should therefore be evaluated separately relative to the benefits they offer. If the relative longevity of ceramic laminates is compared to that of composite resins, the observed results can vary significantly.¹⁰⁻¹³ The esthetic quality and longevity (or durability) of a dental restoration is affected by many factors, including



TABLE 1
Comparison of direct, direct-indirect, and indirect restorations

	Direct (composite resin)	Direct-indirect (composite resin)	Indirect (ceramics)
Level of difficulty	Low to intermediate	Intermediate to high	Intermediate to high
Treatment time	Long	Intermediate	Long
Number of appointments	1-2	1-2	2-3
Quality of margins	Moderate	Excellent	Good to excellent
Alteration of form	Yes	Yes	No
Modulation of color	No	Yes	Yes
Final esthetics	Excellent	Excellent	Excellent
Longevity	Intermediate to high	Intermediate to high	High
Patient comfort	Intermediate	High	Intermediate to high
Cost to dentist	\$	\$	\$\$\$
Cost to patient	\$	\$\$	\$\$\$

the operator, the technique, the materials, the conditions in which the restoration is executed, and, finally, the patient, taking into account their age as well as their eating and personal habits (eg, smoking and parafunction).¹⁴⁻¹⁸ The literature presents clear evidence that composite resins and ceramics are materials that can be used synergistically, according to their best characteristics and properties, for the optimization of clinical results.^{19,20}

Another factor considered by clinicians in choosing a direct or indirect approach is the time required to perform the procedure. It is common to affirm that indirect procedures are more advantageous than direct procedures, from the point of view of predictability, clinical productivity, and financial gain, because they require less clinical chair time in their execution. This statement must be considered only partially true because it depends essentially on the type as well as number of restorations that will be fabricated, not to mention the technical knowledge and training that the operator must have to perform such procedures.²¹ In the over 60 years of combined teaching and clinical experience of the authors, they have learned that it is possible to exponentially optimize the clinical chair time and achieve optimal results of esthetic quality and restorative precision with both techniques through learning and incorporation of methodical protocols.

Current composite resins exhibit esthetic and mechanical properties so similar to enamel and dentin that the operator factor may actually be what ultimately determines the level of satisfaction of our patients, not the restorative material itself.

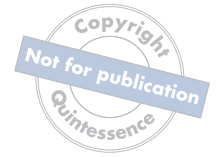

Patient satisfaction is also an essential factor in the selection of either composite resins or ceramics. A study evaluating the degree of satisfaction of patients submitted to three distinct types of veneers—direct resin, indirect resin, and ceramic restorations—demonstrated that patients favored ceramic veneers after 2 years.²² However, current composite resins exhibit esthetic and mechanical properties so similar to enamel and dentin that the operator factor may actually be what ultimately determines the level of satisfaction of our patients, not the restorative material itself.

Composite resins are extremely versatile materials. One of their greatest advantages over indirect restorative materials is that composite resins can be used with minimal reduction of natural tooth structure, given their minimal need for tooth preparation retention and resistance form. This allows for conservation of tooth structure and ultimately results in extended longevity for the tooth-restoration complex.²³ The durability of direct composite resin restorations is affected by material factors, operator factors, and patient factors.^{14,24-28} However, when properly selected and used, these materials can yield excellent and long-lasting results.²⁹⁻³¹

Direct Restorations: The Orthodox Approach

Since their inception, composite resins have been mostly used via a direct technique. As such, the composite resin is directly applied to the tooth structure already adhesively prepared and artistically sculpted by light activating one or more increments to restore color and shape.³² The direct approach enables the operator to evaluate and control the restorative process as much as possible, from color selection to final morphology, and is usually done in a single appointment. For these reasons, the direct technique is the preferred composite resin technique. However, successful esthetic and functional results with the direct technique are not always easy to achieve and depend mainly on the operator's understanding of the adhesive technology, knowledge of the mechanical properties of the composite resins and their optical relationship with the natural tooth structure, correct handling of layering techniques, and proper light curing.³³ Because the process of application, finishing, and polishing is performed entirely intraorally, the direct technique has some disadvantages that can be minimized or even eliminated via the technique proposed in this book, the direct-indirect approach.



Disadvantages inherent to the direct technique include color instability, potential for wear, and polymerization shrinkage, which can result in estimated restoration longevity of 4 to 8 years according to some studies.^{14,27,34} All of these problems relate to the relative inefficiency and poor performance of intraoral light-curing units, either due to poor access to the surface being cured, poor operator technique, or a combination of these factors. Once again, however, the clinical scenario involved in the longevity (durability) of direct restorations is multifactorial, and the triad determined by material, technique, and operator must always be taken into account in the evaluation of causes for failure.

The Indirect Technique

To address the challenges presented by direct restorations, indirect techniques for composite resins have been developed, allowing them to be processed in the laboratory or chairside in the dental office.³⁵ When properly light activated in the presence of vacuum or pressure and subsequently subjected to heat, these types of restorations exhibit greater conversion of monomers to polymers. This optimized conversion can result in improved physical properties of the material, such as increased wear resistance, improved hardness, polymerization shrinkage control, color stability, and enhanced biocompatibility.³⁶ However, the increasing availability of ceramics with high-quality optical properties and excellent mechanical properties has rendered the use of the indirect technique for making composite resin veneers and anterior crowns obsolete.

The Direct-Indirect Technique

Thus, the direct-indirect restorative technique emerged, which brings together many of the advantages present individually in both the direct and the indirect techniques. As the terminology is new, it is necessary to first explain what the direct-indirect technique means. To explain it simply, a direct-indirect restoration is one in which the composite

To explain it simply, a direct-indirect restoration is one in which the composite resin is sculpted DIRECTLY on the tooth structure without previous adhesive preparation, light activated, removed from the tooth, heat tempered, finished and polished extraorally, and finally “bonded” or adhered INDIRECTLY in the mouth in a single appointment.

resin is sculpted DIRECTLY on the tooth structure without previous adhesive preparation, light activated, removed from the tooth, heat tempered, finished and polished extraorally, and finally “bonded” or adhered INDIRECTLY in the mouth in a single appointment (Fig 1). In fact, the technique comprises several important requirements for each of the steps and may present slight variations depending on the clinical procedure. Also called *semidirect*, this technique has clinical applications in the anterior and posterior dentition, and its benefits are widely discussed in the literature.³⁷⁻⁴³ When initially introduced, the major benefits of the technique emphasized the possibility of subjecting intraorally made veneers and inlays to



additional extraoral light and heat treatment in order to optimize the physical properties and clinical behavior of the restorations due to an increase in the polymeric conversion of the organic matrix of the restorative composite resins.^{36,44,45} Although of extreme importance, the optimization of physical properties is just one of the numerous advantages presented by the technique.

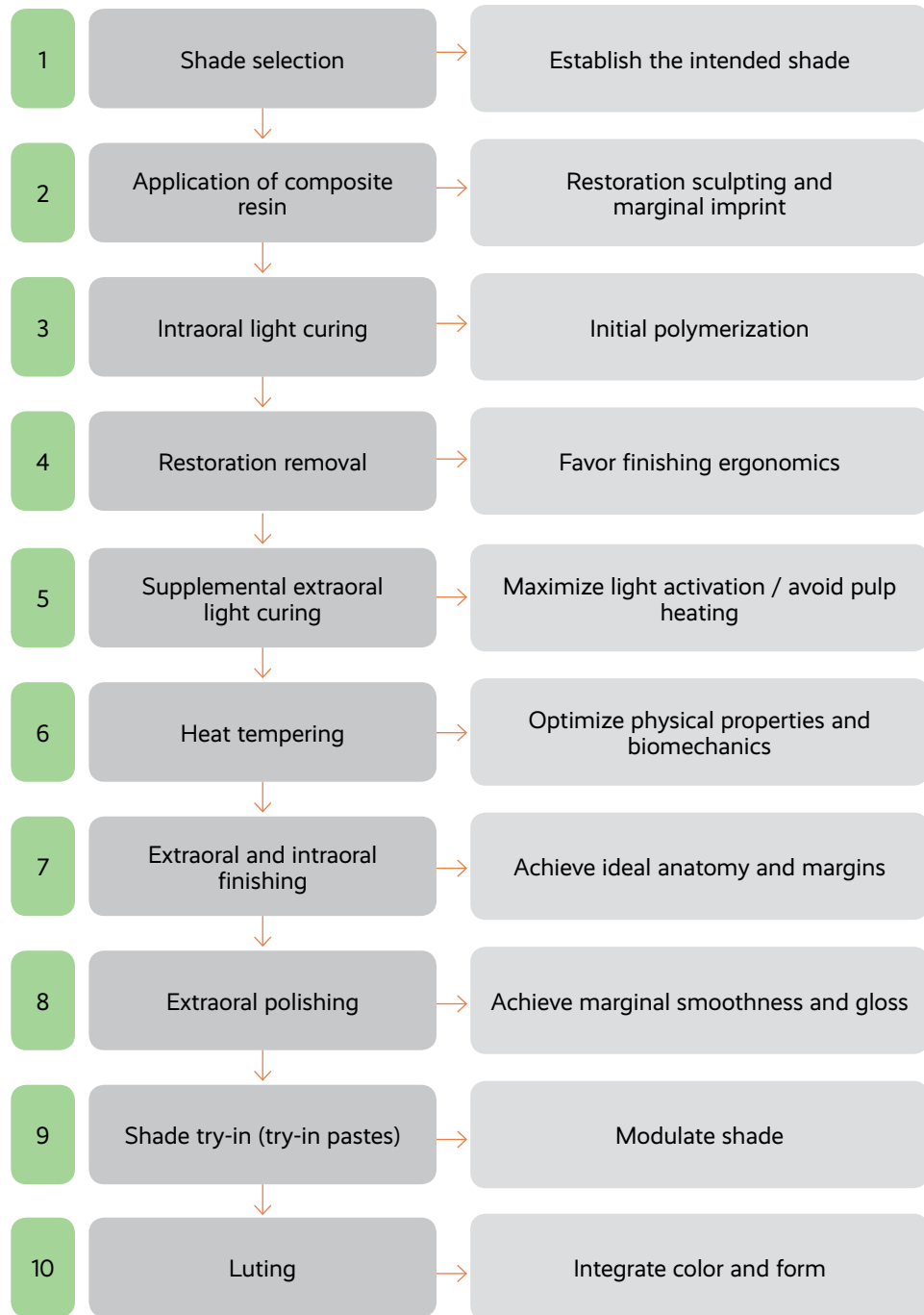Because in the direct-indirect technique the restoration is sculpted directly on the tooth surface and removed after its light activation, it can be thermally treated, finished, and polished prior to processing for adhesion and luting. Thus, the resulting restoration exhibits improved mechanical properties, excellent esthetics, as well as unrivaled marginal adaptation and polishing. Moreover, the marginal gap that may result from polymerization shrinkage of the restoring resin in a direct technique is compensated by the precise adaptation of the directly sculpted veneer in association with a lower film thickness of the resin luting agent.⁴⁶ The absence of a laboratory phase excludes provisionalization and eliminates the costs arising from this step. One of the most significant advantages of this technique, which will be very evident in the course of the book, is the possibility of the operator modulating the final color of the restoration with the luting agents, allowing for minor modifications in the restoration hue, chroma, and value (see chapter 3).

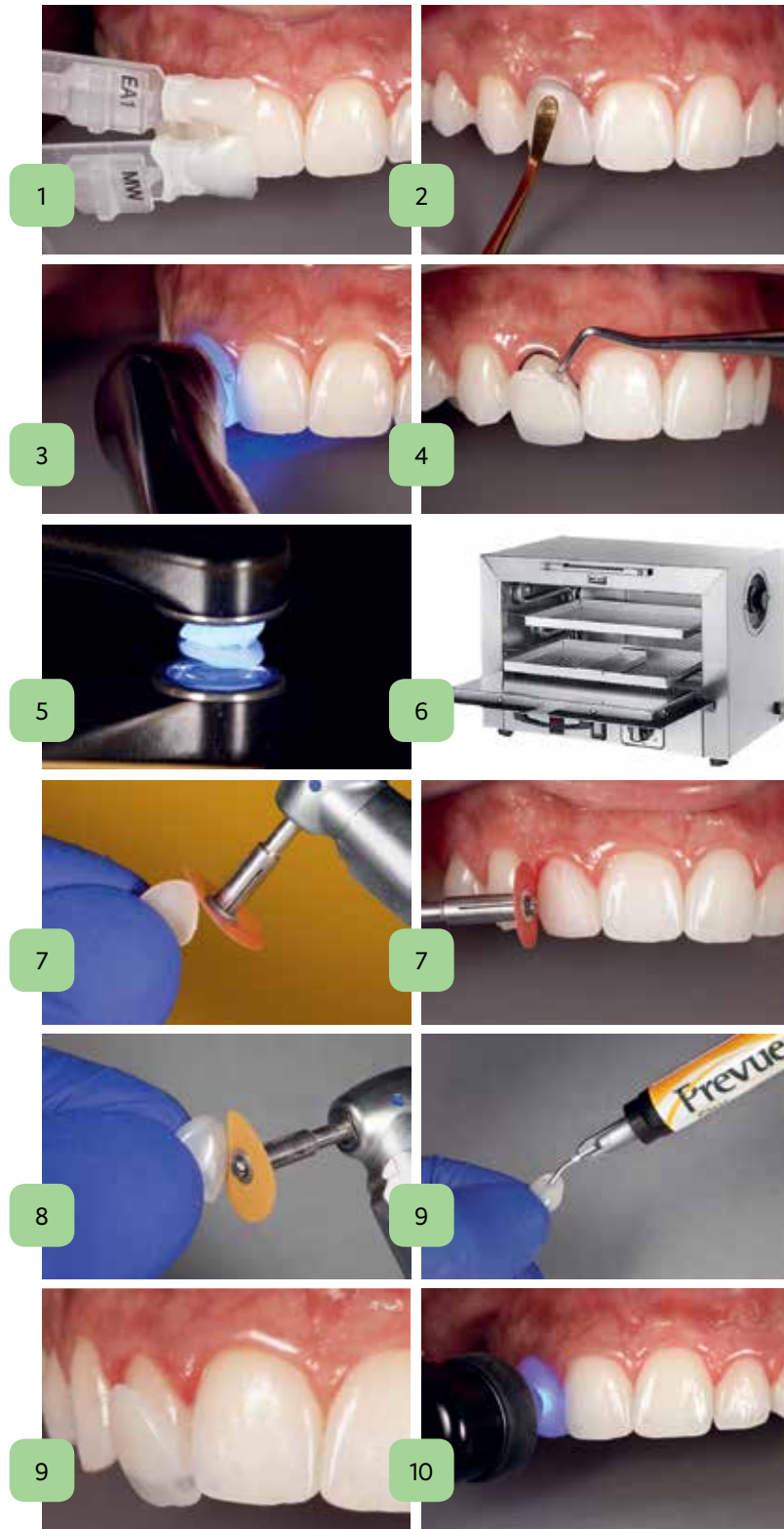
As presented in the chapters that follow, the direct-indirect technique has a wide range of applications, including prepless contact lenses and veneers, veneers with preparation (discolored teeth), fragments, diastema closure, and noncarious cervical lesions, among others. In some situations, the correct shape of microdontia-affected teeth or lingually inclined teeth can be re-established through a thin contact lens-type veneer with only one or two shades. Other times several layers of resins of different shades and opacities are necessary to correct tooth discoloration and achieve a natural mimicry.

The direct-indirect technique requires the operator to have an open mind to incorporate new paradigms into their clinical reality. The audacious learning process might result in a certain amount of discomfort because it involves overcoming unknown challenges, which will naturally push the operator back into his or her comfort zone. As in any other area of dentistry, the mastery of this technique requires focus, a desire to learn, and intense training. The reward will surely come amplified with an unprecedented level of professional and personal satisfaction.



FIG 1
Steps for direct-indirect composite restorations.







Improved Mechanical Properties

LIGHT ACTIVATION

The quality of a composite resin restoration and its clinical behavior are directly related to the degree of polymerization that the material will reach through the light-activation process.^{47,48} Three factors must be present and controlled for this process to take place correctly and fully: wavelength, intensity, and time of exposure. The wavelength comprises the spectral range emitted by the light-curing unit that will activate photoinitiator agents present in the organic matrix of the composite resin. In order to cover the different types of photoinitiators, which vary greatly from product to product, the ideal spectrum must have amplitude between 380 and 520 nm. Outside of this spectrum, light activation will not start properly. QTH (quartz-tungsten-halogen) lamp-based curing units are still currently used and are capable of activating all types of photoinitiators. LED curing lights are today the most prevalent in the market and have gained wide acceptance among the dental community. The clinician should select an LED curing light with a wide spectral range (polywave) to ensure correct photoinitiation. The intensity, or irradiance (measured in mW/cm^2), is the power of the curing unit, responsible for the speed and extent of free radical formation, which breaks the double bonds between the carbon molecules to form more stable cross-linked polymer chains. Finally, time is the factor associated with the intensity producing the energy (mJ/cm^2) required for the conversion process of the monomers into polymers to be complete. The more polymers that are formed, the higher the resistance to fracture and wear of a composite resin, and the better its color stability. Consequently, the better the photopolymerization, the better the mechanical properties and the greater the longevity of the restoration.

The wavelength is standardized for each light-curing unit, and there is nothing the clinician can do to improve its performance. The intensity can be controlled by changing the setting of each light-curing unit, when available, as well as by varying the distance of the light tip to the composite resin being cured. When these two factors are controlled, only the variation of the exposure time and thus the energy supplied may change the quality of the final polymerization of the restoration. In general, it is always prudent to light activate a composite resin for a longer time. Due to the enormous variation of spectral range, heterogeneity of the irradiance in the active tip, and different levels of intensity among the commercially available lights,⁴⁷ it is very difficult to evaluate the efficacy of each light-curing unit. Therefore, to ensure correct light activation of composite resin restorations, some general rules must always be followed:

- Select a light-curing unit with a wide spectrum (380–520 nm).
- Set the curing light to its maximum intensity (ideally above $1,200 \text{ mW}/\text{cm}^2$), being careful to avoid excessive heat output to prevent pulp and soft tissue damage. To prevent this, the tooth should be air cooled when light curing for extended times.⁴⁹



- Use curing lights that have a large-diameter guide (curing tip ≥ 10 mm in diameter).
- Keep the guide tip as close to the resin surface as possible.
- Exceed the exposure time recommended by the manufacturer.

Another benefit of the direct-indirect technique is the longer period of final extraoral light activation than we would normally use in the mouth. The main advantage of this step is that all energy can be supplied to the restoration without running the risk of causing deleterious pulp overheating by the heat emanating from the curing light.

HEAT TEMPERING

Light-cured composite resins undergo a late polymerization called *dark phase polymerization*.⁵⁰ Approximately 75% of the polymerization reaction takes place during the first 10 minutes after light curing, and the process continues for a period of 24 hours,^{51,52} reaching its maximum peak at 7 days.⁵³ Even following an extremely controlled light-activation protocol at room temperature, the monomer-polymer degree of conversion varies between 40% and 75%,^{54,55} thus leaving the restoration susceptible to inherent problems of incomplete polymerization by the presence of unreacted residual monomers.

One of the great benefits of the direct-indirect technique is that the mechanical properties can be optimized through a thermal treatment complementary to the light-induced polymerization, a process called *heat tempering*. When the composite resin is subjected to heat tempering after light curing, the conversion from monomer to polymer is maximized both in quantity and quality of the polymers formed, and a volatilization of residual monomers occurs.⁵⁶ Although it is probable that this is the main factor, it is possible that the increase in temperature also produces a release of the stress formed during the initial polymerization by the annealing process.⁵⁷ This results in immediately improved physical and mechanical properties including stiffness, hardness, modulus of elasticity, flexural strength, hygroscopic expansion, solubility, and color stability. However, there is evidence that composite resins that are not heat tempered still undergo the same improvement as heat-tempered composite resins in the course of time,⁵⁷ prompting the question of whether the extra effort is really necessary. Although the literature is controversial even with respect to the merit of the procedure,^{58,59} the majority of the studies point to the benefits of heat tempering, and therefore the authors recommend its inclusion in the direct-indirect protocol because of the immediate benefits it provides.⁶⁰⁻⁶² There are several heat-tempering methods, but all must employ dry heat, because the aqueous medium may potentially cause hydrolysis between the silane and the inorganic phase of the composite resin, which is undesirable.⁶³



TABLE 2
Composite resin
heat-tempering methods

Equipment	Temperature/power	Time
Microwave oven	450 to 500 W	3–5 min
Electric oven	120°C/248°F	10 min
Heat-pressure polymerization unit	120°C/248°F	10 min
Autoclave	121°C–134°C/250°F–273°F	15 min

Equipment that can be used for this purpose includes the following:

- Microwave oven
- Electric oven
- Heat-pressure polymerization unit
- Autoclave (dry cycle)

The time and temperature regimen described in the literature for the treatment of the light-activated composite resins varies according to the restorative material and the available equipment. Table 2 shows some possibilities.

In general, post-light activation heat tempering enhances the physical and mechanical properties of composite resins. However, it is important to remember that not all composite resins have the same chemical composition, varying in the types of organic matrix; types, size, and percentage of inorganic filler; and the type and amount of photoinitiators. Thus, composite resins with organic and inorganic content more favorable to the improvement by the additional thermal treatment will present a higher degree of polymerization and, consequently, better properties.⁴⁵ For example, composites containing a higher percentage of photoinitiators will undergo a higher initial conversion rate by light activation and, consequently, will exhibit lower monomeric mobility once the glass phase is reached, which will mean that the complementary heat-tempering process has less effect on the improvement of physical and mechanical properties. However, composite resins that reach a lower degree of monomeric conversion by the initial light activation will tend to benefit more from the heat treatment.

Extraoral and Intraoral Finishing

The direct-indirect technique always requires the application of the composite resin with excess and increased thickness in order to achieve a good reproduction of the margins, as well as to facilitate restoration removal after initial intraoral curing without fracturing. Of course, such excesses would become very difficult to remove if finishing

were done only intraorally. As the direct-indirect restoration presents a very similar handling and finishing concept to that of a provisional polymethyl methacrylate (PMMA) restoration, the clinical steps are also very similar. Therefore, the technique allows the visualization of micro and macro details through intra- and extraoral evaluation. The ergonomic mobility that the clinician gains during this phase to determine shape, contours, and subtle detail is extremely optimized because it does not require the use of rubber dam isolation, thus allowing a much greater interaction with the patient in the evaluation of results.

Marginal Adaptation

The choice of restorative composite resin and its correct application determine the degree of marginal adaptation of direct-indirect restorations. As in the direct technique, the use of spatulas, brushes, and other contouring instruments is indicated to obtain a refined anatomy. However, a major paradigm of the direct-indirect technique comprises the extensive use of gentle digital pressure, through finger molding, to make the primary contour of the restoration. This process produces better accommodation and penetration of the material and better impression of margins, depressions, and subgingival zones, in addition to reducing the time of clinical application.

After sculpting and intraoral light activation, the restoration is removed, and the margins are highlighted with a pencil for best visualization. Thereafter the finishing is done sequentially with high- and medium-grit aluminum oxide disks until “knife blade” margins are reached. These extremely fine edges will now be able to receive final polishing.

Polishing

A restoration that is made by the direct technique receives the finishing and polishing of interproximal and subgingival areas with diamond or carbide burs, abrasive strips, rubber rotaries, felt disks, and polishing pastes. There is evidence that single-step rubber-based rotary polishers are effective in achieving a high degree of initial polishing for microfill, nanofill, and hybrid composite resins.^{64,65} However, the quality (smoothness and gloss) of the marginal polishing offered by these instruments cannot be compared with that obtained only with the use of aluminum oxide disks.^{65,66} Aluminum oxide disks are among the best tools for obtaining excellent polishing of composite resins.^{67,68} Because the finishing and polishing of cervical margins of a direct-indirect restoration, as in the case of a veneer, is performed completely extraorally, there is no soft tissue damage, and the immediate clinical outcome always reveals an extremely well-adapted and biologically healthy interface (Fig 2).

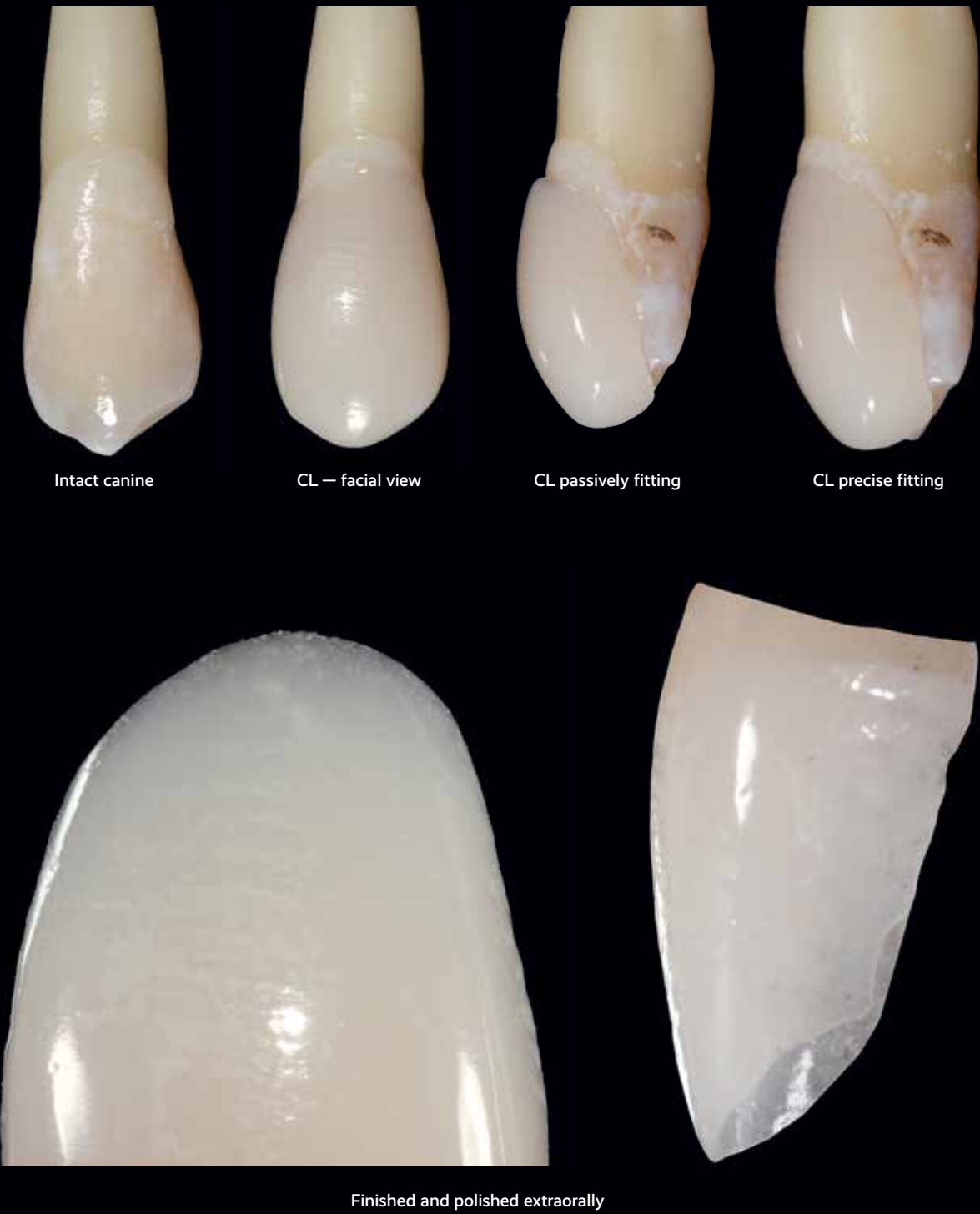
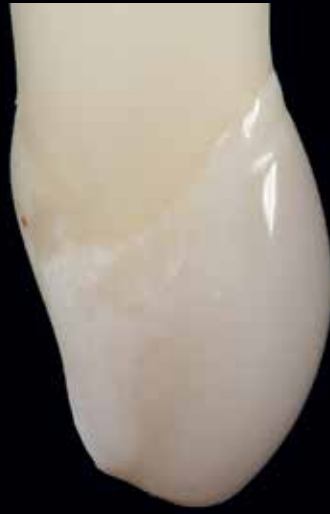
FIG 2 Contact lens (CL) restoration and scanning electron micrograph (SEM) before and after luting. (Courtesy of Marcos Vargas, DDS, MS. Photography courtesy of Rodrigo R. Maia, DDS, MS, PhD.)

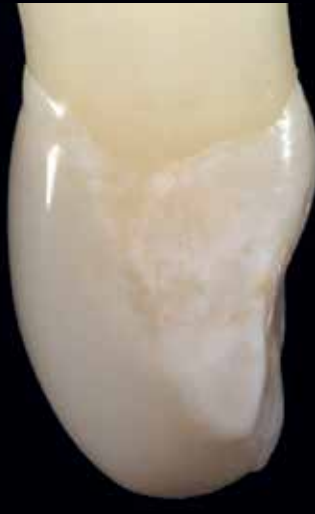Polishing




Luted CL — buccal view



Luted CL — mesial view



Luted CL — distal view



SEM before luting



SEM after luting



Possibility of Corrections

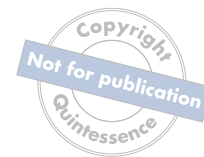Clinical errors are undesirable and unpleasant for both the clinician and the patient. One of the great frustrations in direct composite resin procedures is when something goes wrong after the conclusion of the case, whether immediately or in the postoperative period. Errors are usually related to poor morphology or, more often, color mismatch. In the first case, the correction is quite simple; it suffices for the clinician only to re-touch the anatomy by subtraction or addition of material. When the error is in color, however, the solution may become a bit more laborious, depending on the degree of the mismatch. If any detail or desired color effect was not correct, the solution is in the partial removal or addition of material to the defective layer and its replacement with another layer of correct color. The great difficulty is when the final restoration presents serious errors in hue, chroma, and value. In this case, the clinician will need to completely remove the restoration and start over from the beginning, whether in the same or a subsequent appointment.

The direct-indirect technique offers the great benefit of enabling the clinician the opportunity to perform corrections more quickly in the same defective restoration, or discard it altogether and perform a totally new one, already contemplating the necessary changes. The major advantage is in the ability to perform minor chroma and value modulations, and to a lesser degree, hue, through try-in pastes. These pastes have varying degrees of opacity, hue, and saturation, which interfere with the color inherent in a direct-indirect contact lens or veneer. The opacity and thickness of the composite resin used in the restoration directly impact the ability to modulate the color through the luting resin, hence the importance of the correct choice and application of restorative and luting material so that the necessary color modulations can be performed effectively. As will be discussed in chapter 3, mastery of the four-dimensional color system is essential for the clinician to achieve the desired results through try-in pastes and luting resins.

The major advantage is in the ability to perform minor chroma and value modulations, and to a lesser degree, hue, through try-in type pastes.

References

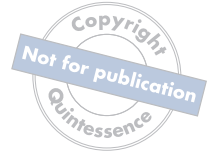1. Ammannato R, Ferraris F, Allegri M. The "index cutback technique": A three-dimensional guided layering approach in direct class IV composite restorations. *Int J Esthet Dent* 2017;12:450–466.
2. Dietschi D, Fahl N Jr. Shading concepts and layering techniques to master direct anterior composite restorations: An update. *Br Dent J* 2016;221:765–771.
3. Black JB. Esthetic restoration of tetracycline-stained teeth. *J Am Dent Assoc* 1982;104:846–852.
4. Bogosavljević A, Misina V, Jordacević J, et al. Treatment of teeth in the esthetic zone in a patient with amelogenesis imperfecta using composite veneers and the clear matrix technique: A case report. *Vojnosanit Pregl* 2016;73:288–292.
5. Carvalho LD, Bernardon JK, Bruzi G, Andrada MA, Vieira LC. Hypoplastic enamel treatment in permanent anterior teeth of a child. *Oper Dent* 2013;38:363–368.



6. Chalkley Y. Treatment of a single stained anterior tooth utilizing visible-light-cured opaquer resin and microfil composite resin. *Iowa Dent J* 1984;70:37–39.
7. Heymann HO, Ritter AV. Additional conservative esthetic procedures. In: Ritter AV, Boushell L, Walter R (eds). *Sturdevant's Art and Science of Operative Dentistry*, ed 7. St Louis: Elsevier, 2019: 264–305.
8. Perdigão J, Lam VQ, Burseth BG, Real C. Masking of enamel fluorosis discolorations and tooth misalignment with a combination of at-home whitening, resin infiltration, and direct composite restorations. *Oper Dent* 2017;42:347–356.
9. Pollack BF, Blitzer MH. Esthetic veneering: Materials and techniques. *Gen Dent* 1983;31:483–488.
10. Dunn J. Direct composite or bonded porcelain: A clinical choice for anterior aesthetics. *J Calif Dent Assoc* 22:73–76,78,80–81.
11. Friedman MJ. A 15-year review of porcelain veneer failure—A clinician's observations. *Compend Contin Educ Dent* 1998;19:625–628,630,632,638.
12. Meijering AC, Creugers NH, Roeters FJ, Mulder J. Survival of three types of veneer restorations in a clinical trial: A 2.5-year interim evaluation. *J Dent* 1998;26:563–568.
13. Peumans M, De Munck J, Fieuws S, Lambrechts P, Vanherle G, Van Meerbeek B. A prospective ten-year clinical trial of porcelain veneers. *J Adhes Dent* 2004;6:65–76.
14. Collares K, Opdam NJM, Laske M, et al. Longevity of anterior composite restorations in a general dental practice-based network. *J Dent Res* 2017;96:1092–1099.
15. Poggio C, Vialba L, Berardengo A, et al. Color stability of new esthetic restorative materials: A spectrophotometric analysis. *J Funct Biomater* 2017;8:E26.
16. Smales RJ. Effects of enamel-bonding, type of restoration, patient age and operator on the longevity of an anterior composite resin. *Am J Dent* 1991;4:130–133.
17. Smales RJ, Gerke DC. Clinical evaluation of light-cured anterior resin composites over periods of up to 4 years. *Am J Dent* 1992;5:208–212.
18. Smales RJ, Gerke DC. Clinical evaluation of four anterior composite resins over five years. *Dent Mater* 1992;8:246–251.
19. Gerdolle D, Mortier E, Richard A, Vailati F. Full-mouth adhesive rehabilitation in a case of amelogenesis imperfecta: A 5-year follow-up case report. *Int J Esthet Dent* 2015;10:12–31.
20. Vailati F, Belser UC. Full-mouth adhesive rehabilitation of a severely eroded dentition: The three-step technique. Part 3. *Eur J Esthet Dent* 2008;3:236–257.
21. Meijering AC, Creugers NH, Mulder J, Roeters FJ. Treatment times for three different types of veneer restorations. *J Dent* 1995;23:21–26.
22. Meijering AC, Roeters FJ, Mulder J, Creugers NH. Patients' satisfaction with different types of veneer restorations. *J Dent* 1997;25:493–497.
23. ADA Council on Scientific Affairs. Direct and indirect restorative materials. *J Am Dent Assoc* 2003;134:463–472.
24. Casagrande L, Seminario AT, Correa MB, et al. Longevity and associated risk factors in adhesive restorations of young permanent teeth after complete and selective caries removal: A retrospective study. *Clin Oral Investig* 2017;21:847–855.
25. Pinto Gdos S, Oliveira LJ, Romano AR, et al. Longevity of posterior restorations in primary teeth: Results from a paediatric dental clinic. *J Dent* 2014;42:1248–1254.
26. Demarco FF, Corrêa MB, Cenci MS, Moraes RR, Opdam NJ. Longevity of posterior composite restorations: Not only a matter of materials. *Dent Mater* 2012;28:87–101.
27. Opdam N. Clinical trials: Randomization, completeness of data and restoration longevity. *Dent Mater* 2016;32:489–491.
28. Opdam NJ, Bronkhorst EM, Cenci MS, Huysmans MC, Wilson NH. Age of failed restorations: A deceptive longevity parameter. *J Dent* 2011;39:225–230.
29. Coelho-de-Souza FH, Gonçalves DS, Sales MP, et al. Direct anterior composite veneers in vital and non-vital teeth: A retrospective clinical evaluation. *J Dent* 2015;43:1330–1336.
30. Kim KH, Ong JL, Okuno O. The effect of filler loading and morphology on the mechanical properties of contemporary composites. *J Prosthet Dent* 2002;87:642–649.
31. Valente LL, Peralta SL, Ogliaeri FA, Cavalcante LM, Moraes RR. Comparative evaluation of dental resin composites based on micron- and submicron-sized monomodal glass filler particles. *Dent Mater* 2013;29:1182–1187.
32. Fahl N Jr. Achieving ultimate anterior esthetics with a new microhybrid composite. *Compend Contin Educ Dent Suppl* 2000;26:4–13.



33. Fahl N Jr, Denehy GE, Jackson RD. Protocol for predictable restoration of anterior teeth with composite resins. *Pract Periodontics Aesthet Dent* 1995;7:13–21.
34. Albers HF. *Tooth-Colored Restoratives: Principles and Techniques*. Hamilton, ON: BC Decker, 2001.
35. Heymann HO. Indirect composite resin veneers: Clinical technique and two-year observations. *Quintessence Int* 1987;18:111–118.
36. Ferracane JL, Condon JR. Post-cure heat treatments for composites: Properties and fractography. *Dent Mater* 1992;8:290–295.
37. Birnbaum NS. Direct oven-tempered hybrid composite-resin laminate veneers. *Pract Periodontics Aesthet Dent* 1992;4:23–31.
38. Birnbaum NS. Heat-tempered composite resin laminate veneers. *Curr Opin Cosmet Dent* 1994;52–57.
39. Blankenau RJ, Kelsey WP 3rd, Cavel WT. A direct posterior restorative resin inlay technique. *Quintessence Int Dent Dig* 1984;15:515–516.
40. Dietschi D, Spreafico R. *Adhesive Metal-Free Restorations. Current Concepts for the Esthetic Treatment of Posterior Teeth*. Chicago: Quintessence, 1997.
41. Fahl N Jr. Direct-indirect class V restorations: A novel approach for treating noncarious cervical lesions. *J Esthet Restor Dent* 2015;27:267–284.
42. Magne P. Noninvasive bilaminar CAD/CAM composite resin veneers: A semi-(in)direct approach. *Int J Esthet Dent* 2017;12:134–154.
43. Fahl N Jr. The direct/indirect composite resin veneers: A case report. *Pract Periodontics Aesthet Dent* 1996;8:627–638.
44. Covey DA, Tahaney SR, Davenport JM. Mechanical properties of heat-treated composite resin restorative materials. *J Prosthet Dent* 1992;68:458–461.
45. Wassell RW, McCabe JF, Walls AW. Wear rates of regular and tempered composites. *J Dent* 1997;25:49–52.
46. Titus HW, Chan DC. A comparison of gingival marginal gap formation in composite inlays using three different fabrication techniques. *Tex Dent J* 1992;109:13–16.
47. Rueggeberg FA, Giannini M, Arrais CAG, Price RBT. Light curing in dentistry and clinical implications: A literature review. *Braz Oral Res* 2017;31(suppl 1):e61.
48. Price RB, Shortall AC, Palin WM. Contemporary issues in light curing. *Oper Dent* 2014;39:4–14.
49. Price RB. Light curing guidelines for practitioners: A consensus statement from the 2014 Symposium on Light Curing in Dentistry, Dalhousie University, Halifax, Canada. *J Can Dent Assoc* 2014;80:e61.
50. Pilo R, Cardash HS. Post-irradiation polymerization of different anterior and posterior visible light-activated resin composites. *Dent Mater* 1992;8:299–304.
51. Chung KH, Greener EH. Correlation between degree of conversion, filler concentration and mechanical properties of posterior composite resins. *J Oral Rehabil* 1990;17:487–494.
52. Ferracane JL, Greener EH. The effect of resin formulation on the degree of conversion and mechanical properties of dental restorative resins. *J Biomed Mater Res* 1986;20:121–131.
53. Marghalani HY. Effect of finishing/polishing systems on the surface roughness of novel posterior composites. *J Esthet Restor Dent* 2010;22:127–138.
54. Eliades GC, Vougiouklakis GJ, Caputo AA. Degree of double bond conversion in light-cured composites. *Dent Mater* 1987;3:19–25.
55. Chung K, Greener EH. Degree of conversion of seven visible light-cured posterior composites. *J Oral Rehabil* 1988;15:555–560.
56. Cook WD, Johannson M. The influence of postcuring on the fracture properties of photo-cured dimethacrylate based dental composite resin. *J Biomed Mater Res* 1987;21:979–989.
57. de Gee AJ, Pallav P, Werner A, Davidson CL. Annealing as a mechanism of increasing wear resistance of composites. *Dent Mater* 1990;6:266–270.
58. McCabe JF, Kagi S. Mechanical properties of a composite inlay material following post-curing. *Br Dent J* 1991;171:246–248.
59. Peutzfeldt A, Asmussen E. Mechanical properties of three composite resins for the inlay/onlay technique. *J Prosthet Dent* 1991;66:322–324.
60. Peutzfeldt A, Asmussen E. The effect of postcuring on quantity of remaining double bonds, mechanical properties, and in vitro wear of two resin composites. *J Dent* 2000;28:447–452.
61. Reinhardt JW, Boyer DB, Stephens NH. Effects of secondary curing on indirect posterior composite resins. *Oper Dent* 1994;19:217–220.



62. Takeshige F, Kinomoto Y, Torii M. Additional heat-curing of light-cured composite resin for inlay restoration. *J Osaka Univ Dent Sch* 1995;35:59–66.
63. Shah MB, Ferracane JL, Kruzic JJ. R-curve behavior and micromechanisms of fracture in resin based dental restorative composites. *J Mech Behav Biomed Mater* 2009;2:502–511.
64. Paravina RD, Roeder L, Lu H, Vogel K, Powers JM. Effect of finishing and polishing procedures on surface roughness, gloss and color of resin-based composites. *Am J Dent* 2004;17:262–266.
65. Da Costa J, Ferracane J, Paravina RD, Mazur RF, Roeder L. The effect of different polishing systems on surface roughness and gloss of various resin composites. *J Esthet Restor Dent* 2007;19: 214–224.
66. da Costa JB, Gonçalves F, Ferracane JL. Comparison of two-step versus four-step composite finishing/ polishing disc systems: Evaluation of a new two-step composite polishing disc system. *Oper Dent* 2011;36:205–212.
67. Barbosa SH, Zanata RL, Navarro MF, Nunes OB. Effect of different finishing and polishing techniques on the surface roughness of microfilled, hybrid and packable composite resins. *Braz Dent J* 2005;16:39–44.
68. Kamedini RR, Penumatsa NV, Priya T, Baroudi K. The influence of finishing/polishing time and cooling system on surface roughness and microhardness of two different types of composite resin restorations. *J Int Soc Prev Community Dent* 2014;4(suppl 2):S99–S104.

Index



Page references followed by “f” denote figures and “t” denote tables.

A

Acid etching, 101
Adhesive luting, 102, 103f
Adhesives, dental
 classification of, 101
 etch-and-rinse, 101, 184, 266
 self-etch, 101, 183, 266, 278
Airborne-particle abrasion, 101–102, 171, 185, 266, 267f, 276
Alginate impressions, 217
Aluminum oxide disks, 11, 98, 264f, 267f, 270f, 271
Artificial dentin
 application of, 137, 148, 158
 polychromatic layering of, 27, 28f, 31t
 shades of, 27, 29
Artificial enamel, 27, 137
Atomic force microscopy, 255f

B

Bis-acryl mock-up, 218
Bleach body enamel, 159
Bleaching, 131–132, 154, 173
Blending effect, 21
Blue, 36f, 38f
Body and value enamels, with Type 1 contact lens, 49, 51f
Body enamels
 bleach, 159
 cervical, 159
 composite resins and, 47
 description of, 29, 31t, 207
 high-chroma, 176
 with Type 1 contact lens, 49, 50f
Bonding
 adhesive protocol for, 100–102, 183–186
 illustration of, 140, 150, 164, 178
Brown, 37f
Burs, 104, 180

C

CAD/CAM technology, 1
Ceramics
 composite resins versus, 1, 2t
 patient satisfaction with, 3
Cervical body enamel, 159
Chameleon-like effect, 21
Chroma, 93, 147, 170
Class V composite inlays. *See* Direct-indirect Class V restoration.
Color
 mismatch of, 14
 tints for. *See* Tints.
Composite crown, 197
Composite resin(s)
 advancements in, 19
 advantages of, 43
 in anterior teeth, 20
 application technique for, 96–98, 97t
 ceramics versus, 1, 2t
 clinical longevity of, 1, 2t
 color properties of, 21–25
 contact lenses affected by, 47, 47f
 contouring of, 98–99
 defects corrected using, 1
 direct technique for, 1–4, 3–4
 for direct-indirect Class V restoration, 257–259, 258t
 extra- and intraoral finishing of, 10–11

 finishing of, 98–99
 fluorescence of, 22–24, 23f–24f
 fluorescent, 23–24
 gingiva-colored, 260f
 gingival margins for, 96
 handling of, 20–21, 252
 heat tempering of, 9–10, 10t, 99
 indirect technique for, 1–2, 2t, 4
 iridescence of, 25
 layering concepts for, 26–28
 light activation of, 8–9
 light curing of, 98
 marginal adaptation determined by, 11
 mechanical roughness of, 100
 microfill, 20
 microhybrid, 20–21
 nanohybrid, 20
 for noncarious cervical lesions, 250
 opacity of, 22
 opalescence of, 25, 25f
 optical properties of, 21–25
 patient satisfaction with, 3
 polishing of, 11, 12f–13f, 98–99
 properties of, 2, 20–25
 sculpting/sculptability of, 20–21, 96, 252
 selection criteria for, 2, 20–25
 shading of, 26
 thickness of layer, 96
 tooth preparation for, 96
 tooth-colored, 258, 260f
 translucency of, 22
 uses of, 1–3
 for veneers for discolored teeth, 169–179
 wear rate of, 257
Composite resin systems
 fluorescence of, 24
 selection of, 30–31
 shading-based classification of, 26, 32t
 types of, 32t–33t
 viscosities of, 20
Contact lens effect, 43
Contact lens restoration, 12f
Contact lenses, prepress
 benefit of, 45
 bonding of, 184
 chip on direct veneer with shade mismatch treated with, 66–76
 clinical indications for, 44–45
 composite resin material effects on, 47, 47f
 definition of, 43, 45
 enamel abrasion/erosion treated with, 45
 fabrication of, 48
 facioincisal line angle for, 98
 heteromorphic teeth treated with, 44, 54–64, 116–122
 illustration of, 46f
 indications for, 44–45
 light curing of, 99
 luting resins with, 48
 missing maxillary right central incisor restored with, 106–115
 on multiple teeth, 220–233
 primary anatomy refinement, 102, 103f
 secondary anatomy, 104
 show-through in, 92
 silver powder or glitter over, 102, 103f
 tertiary anatomy, 104
 tooth preparation for, 96
 tooth substrate color for, 46

- Type 1, 49, 50f–51f
 - Type 2, 52–64
 - Type 3
 - case study of, 66
 - central and lateral incisors restored with, 204–214
 - characteristics of, 65–76
 - veneers versus, 43, 44t
 - Corrections, 14
 - Creative Color Opaquer, 169–170, 170f
 - Crown lengthening, 237
- D**
- Dark phase polymerization, 9
 - Dental adhesives, 101
 - Dentin
 - airborne-particle abrasion of, 266, 267f
 - artificial
 - application of, 137, 148, 158
 - polychromatic layering of, 27, 28f, 31t
 - shades of, 27, 29
 - blue fluorescence of, 22
 - bonding to, 183
 - color of, 22, 23f
 - discoloration of, 158
 - fluorescence of, 22–23
 - immediate dentin sealing, 185
 - opacity of, 22
 - sclerotic, 265–266
 - Dentin layer, 180
 - Direct restorations
 - characteristics of, 1–2, 2t
 - color mismatch with, 14
 - corrections necessary for, 14
 - description of, 3–4
 - disadvantages of, 4
 - errors associated with, 14
 - Direct-indirect Class V restoration
 - case study of, 271–280
 - characteristics of, 251t
 - composite handling with, 251t, 252
 - development of, 250
 - difficult-to-reach areas accessed with, 250
 - direct Class V restoration versus, 251t
 - field control using, 251, 251t
 - gingival margin finishing, 251t, 252
 - illustration of, 256f
 - marginal finishing for, 251t, 252
 - operator ergonomics with, 251t, 256–257
 - patient comfort with, 251t, 256
 - periodontal health with, 253
 - polymerization shrinkage-related stress on tooth, 251t, 252
 - postoperative evaluation of, 271
 - restoration marginal adaptation, 251t, 253
 - scanning electron microscopy image of, 254f
 - technique for
 - composite application, 261, 262f
 - composite resin selection, 257–259, 258t
 - extraoral finishing and polishing, 264
 - finishing, 270f, 270–271
 - layering, 258–259, 259f
 - light activation, 262–263
 - luting, 268, 269f
 - polishing, 270f, 270–271
 - preluting surface treatment, 264–268
 - restoration removal, 262–263
 - tooth preparation, 261
 - Direct-indirect restorations
 - adhesive protocol for bonding, 100–102
 - advantages of, 4–5, 9, 92
 - applications of, 5
 - characteristics of, 1–2, 2t
 - corrections with, 14
 - definition of, 4–5, 92
 - extra- and intraoral finishing of, 10–11
 - finishing of, 104, 105t
 - heat tempering, 9–10, 10t
 - indirect restorations versus, 192t
 - marginal adaptation of, 11
 - operator challenges with, 5
 - polishing of, 11, 12f–13f, 104, 105t
 - sandblasting of, 92
 - steps for, 6f–7f, 97t
 - Direct-indirect veneers, 127
 - Discolored teeth
 - maxillary central incisors
 - direct composite restoration for, 172–179
 - unsuccessful whitening, veneers for, 129–142
 - veneers for
 - composite resins for, 169–179
 - layering, 169–170, 180–182
 - material selection, 169–170
 - maxillary left central incisor, 129–142, 153–168
 - maxillary right central incisor, 145–151
 - opaquers for, 169–170, 180
 - tooth preparation for, 127–128, 143–168
 - tooth surface treatment, 183
 - Dry heat, 9
- E**
- Emergence profile, 99, 160
 - Enamel
 - abrasion of, 45
 - airborne-particle abrasion of, 266, 267f
 - artificial, 27, 137, 148
 - blue fluorescence of, 22
 - body. *See* Body enamels.
 - dentin color transmitted by, 22, 23f
 - erosion of, 45
 - etch pattern on, 101
 - fluorescence of, 22–23
 - iridescence of, 25, 25f
 - milky-white semitranslucent. *See* Milky-white semitranslucent enamels.
 - opacity of, 22, 23f
 - opalescence of, 25, 25f
 - polychromatic layering of, 27, 28f
 - shades of, 29–30
 - surface treatment of, for luting, 103f
 - translucency of, 22
 - translucent effect, 30, 31t
 - value. *See* Value enamels.
 - Enamel lingual shell, 157
 - Estelite Color system
 - opaquers, 38, 39f, 39t, 89, 170, 171f
 - tints, 35, 38f
 - Etch-and-rinse adhesives, 101, 184, 266
 - Extraoral finishing, of direct-indirect restorations, 10–11
- F**
- Facial planes, 99
 - Facioincisal line angle, 98–99
 - Field control, for direct-indirect Class V restoration, 251, 251t
 - Finishing
 - of composite resins, 98–99
 - of direct-indirect Class V restoration, 270f, 270–271
 - extraoral, 10–11
 - of gingival margins, 261, 262f
 - intraoral, 10–11

marginal, for direct-indirect Class V restoration, 251t, 252
 of veneers, 104, 105t, 111, 139, 177, 186

Flexible die indirect technique
 bis-acryl mock-up, 218
 digital case optimization, 216
 esthetic evaluation appointment, 218
 fabrication stage, 218
 first appointment, 215–218
 fit-checking cast, 218–219
 impressions, 217–218
 mock-up, 216–217
 photographic documentation, 216
 second appointment, 219
 shade selection, 217
 try-in, 219
 working models, 217–218, 225

Fluorescence, of composite resins, 22–24, 23f–24f

Free gingival margin, 261, 262f

G

Gingival margins
 description of, 96
 finishing of, 261, 262f

Gingivoplasty, 107

Gray, 37f–38f

H

Heat tempering, 9–10, 10t, 99, 183, 263

Heteromorphic teeth
 maxillary canines, and misaligned maxillary lateral incisors, 116–122
 prepress contact lenses for, 44, 54–64, 116–122

High-chroma dentin, 175

Hue, 93, 147

Hydrophobic adhesive, 265f, 268f

I

Immediate dentin sealing, 185

Impressions, for indirect restorations, 217–218

Incisors. *See* Maxillary central incisors; Maxillary lateral incisors.

Indirect restorations
 advantages of, 2, 4
 anatomical refinement of, 219
 case studies of, 193–214, 219–245
 characteristics of, 1–2, 2t
 direct-indirect restorations versus, 192t
 flexible die model workflow for. *See* Flexible die indirect technique.
 on flexible silicone models
 case studies of, 193–214
 technique for, 191
 luting of, 219
 polishing of, 219
 protective splint for, 219
 time requirements for, 2
 try-in of, 219, 241

Inlays, Class V composite. *See* Direct-indirect Class V restoration.

Intraoral finishing, of direct-indirect restorations, 10–11

Intraoral layering, 198

Iridescence, 25, 25f

L

Lavender, 36f

Layering, 110
 of composite resins, 26–28
 direct-indirect Class V restoration, 258–259, 259f

intraoral, 198

polychromatic
 description of, 27
 for direct-indirect Class V restoration, 258
 illustration of, 28f
 polychromatic effects created using, 34, 36f
 selection of, 30–33

LCO. *See* Low chroma opaque.

LED curing lights, 8

Light activation, of composite resins
 description of, 8–9, 262–263, 263f
 heat tempering after, 9–10, 263

Light curing

of composite resins, 98
 of contact lenses, 99
 equipment for, 8–9

supplemental, 99

of veneers, 99, 183

Light-curing units, 8–9

Lingually positioned teeth, veneers for, 45

Low chroma opaque, 170

Low-chroma dentin, 175

Luting, 73, 113, 211

of contact lens restoration, 12f–13f

of direct-indirect Class V restoration, 268, 269f

enamel surface treatment for, 103f

primary anatomy refinement after, 102, 103f, 161, 165, 200

secondary anatomy after, 104, 166–167, 200

tertiary anatomy after, 104, 166–167

Luting resins

chroma of, 93–94

color of, 92–93

description of, 48

hue of, 93

opacity of, 92–93

thickness of, 92

translucency of, 93

try-in pastes and, 93–94, 94f

value of, 93–94

M

Malaligned teeth, veneers for, 45

Marginal adaptation, 11, 251t, 253

Marginal finishing, for direct-indirect Class V restoration, 251t, 252

Maxillary canines, heteromorphic, 116–122

Maxillary central incisors

contact lenses for restoration of

example of, 46f

Type 3, 204–214

discolored

direct composite restoration for, 172–179

unsuccessful whitening, veneers for, 129–142

missing, lateral incisor used to replace, 106–115

Maxillary lateral incisors

heteromorphic, 54–64

misaligned, heteromorphic maxillary canines and, 116–122

peg, 44, 87–91

Type 3 contact lenses for restoration of, 204–214

MCO. *See* Medium chroma opaque.

Medium chroma opaque, 170

Microdontia, 44

Microfill composite resins

description of, 20

sculptability of, 20

Microhybrid composite resins

description of, 20

- sculptability of, 21
thixotropic properties of, 21
Type 2 contact lens with, 53
- Milky-white semitranslucent enamels
description of, 30, 31t, 180
Type 2 contact lens with, 53
- N**
- Nanofill composite resins, 20
- Nanohybrid composite resins
description of, 20
sculptability of, 21
Type 2 contact lens with, 53
- Natural layering shading system, 27, 258
- NCCLs. *See* Noncarious cervical lesions.
- NLS system. *See* Natural layering shading system.
- Noncarious cervical lesions
case study of, 272–280
categorization of, 258, 259f
cavitation of, 259f
composite resins for, 250
definition of, 249
direct-indirect Class V restoration for. *See* Direct-indirect Class V restoration.
illustration of, 249f
preluting surface treatment of, 265f, 265–267, 267f
restoration of, 249
sclerotic dentin with, 265–266
short teeth and deficient direct composite resin restorations with, 78–85
- Non-VITA/non-VITA systems, 26
- Non-VITA/VITA systems, 26, 258
- O**
- Ochre, 35, 36f, 38f
- Opacity
of composite resins, 22
of luting resins, 92–93
of opaquers, 39
veneer thickness and, 92
- Opacity, 25, 25f
- Opaquer(s)
amount to apply, 40
application of, 137
case studies of, 158
Creative Color, 169–170, 170f
definition of, 38
for discolored teeth, 169–170, 180
Estelite Color, 38, 39f, 39t, 89, 170, 171f
film thickness of, 40
layering of, 40
masking effect of, 181
opacity of, 39
opaquing effect of, 38
overapplication of, 40
reason for using, 38
selection of, 40
- Opaquer + ochre + red, 37f
- P**
- Patient satisfaction, 3
- Peg lateral incisors, 44, 87–91
- Periodontal health, 253
- Phosphoric acid, 101
- PMMA. *See* Polymethyl methacrylate.
- Polishing, 111–112
aluminum oxide disks for, 11, 98, 264f, 267f, 270f, 271
of composite resins, 11, 12f–13f, 98–99
of direct-indirect Class V restoration, 270f, 270–271
of direct-indirect restorations, 104, 105t
of veneers, 139, 186
- Polychromatic effects, 34, 36f
- Polychromatic layers/layering
description of, 27
for direct-indirect Class V restoration, 258
illustration of, 28f
polychromatic effects created using, 34, 36f
selection of, 30–33
- Polymerization, dark phase, 9
- Polymerization shrinkage, 4, 251t, 252
- Polymethyl methacrylate, 11
- Polyvinyl siloxane, 217
- Post-crown lengthening, 237
- Prepress veneers. *See* Contact lens(es).
- Primary anatomy refinement, 102, 103f, 161, 165, 200
- Q**
- Quartz-tungsten-halogen lamp-based curing units, 8
- R**
- Red, 35, 37f–38f
- Restorations. *See also* specific restoration.
esthetic quality and longevity of, 1–2
luting resin applied to, 101f
removal of, 98
- Retraction cords, 261, 262f
- Rotary polishers, 11
- Rubber-based rotary polishers, 11
- S**
- Sandblasting, 92
- Sclerotic dentin, 265–266
- Secondary anatomy, 104, 166–167, 200
- Selective-etch approach, 185–186, 271–280
- Self-etch adhesives, 101, 183, 266, 278
- Semidirect technique, 4
- Shade/shading
composite resin systems based on, 26, 32t
mismatch of
chip on direct veneer with, contact lenses for, 66–76
discolored maxillary peg lateral incisors with, 86–91
try-in technique for, 71, 82, 94–95, 95f, 162, 177, 199, 228
- Silanation, 100
- Silicone matrix, 174
- Soft tissue conditioner, 108
- Subgingival margins, 104
- Submicron-filled composites, 257
- T**
- Tertiary anatomy, 104, 166–167
- Tints
definition of, 34
Estelite Color system, 35, 38f
illustration of, 176
indications for, 34
internal uses of, 35
selection of, 35
supplemental uses of, 34
- Tooth crowding, 45
- Tooth preparation
for composite resins, 96
for contact lenses, prepress, 96
for veneers. *See* Veneers, with tooth preparation.
- Tooth substrate color, for prepress contact lenses, 46

- Tooth whitening
 oxidation process from, 22
 unsuccessful, discolored endodontically treated
 maxillary left central incisor with, 129–142
- Total-etch approach, 185
- Trans enamel, 158, 176
- Translucency
 of composite resins, 22
 of luting resins, 93
- Translucent effect enamels, 30, 31t
- Try-in, of indirect restorations, 219, 241
- Try-in pastes, 93–94, 94f
- Type 1 contact lenses, 49, 50f–51f
- Type 1 veneer
 case study of, 78–85
 cervical chamfer in, 144
 characteristics of, 77
 discolored maxillary right central incisor treated with,
 145–151
 indications for, 144
 layering sequence for, 182
 tooth preparation for, 144–151
- Type 2 veneer versus, 86
- Type 2 contact lenses, 52–64
- Type 2 veneer
 case study of, 87–91
 characteristics of, 86
 discolored maxillary left central incisor treated with,
 153–168
 layering sequence for, 182
 tooth preparation for, 152–168
- Type 1 veneer versus, 86
- Type 3 contact lenses
 case study of, 66
 central and lateral incisors restored with, 204–214
 characteristics of, 65–76
- U**
- Ultraviolet light, 22–24
- UV light. *See* Ultraviolet light.
- V**
- Value, 93
- Value check, 147
- Value enamels
 description of, 30, 31t
 illustration of, 160, 176, 207
 with Type 1 contact lens, 49, 50f
- Veneers
 axial reduction for, 143
 bonding of, adhesive protocol for, 183–186
 clinical indications for, 44–45, 127
 contouring of, 183
 definition of, 43
 on dentin with enamel margins, 185
 direct, with shade mismatch and chip, 66–76
 direct-indirect, 127, 171
 discolored teeth treated with
 composite resins for, 169–179
 layering, 169–170, 180–182
 material selection, 169–170
 maxillary left central incisor, 129–142, 153–168
 maxillary right central incisor, 145–151
 opaquers for, 169–170, 180
 tooth preparation for, 127–128, 143–168
 tooth surface treatment, 183
 fabrication of, 48
 facioincisal line angle for, 98
 finishing of, 104, 105t, 177, 186
 laminate, 127
 light curing of, 99, 183
 lingually positioned teeth treated with, 45
 malaligned teeth treated with, 45
 maxillary left central incisor with unsuccessful
 whitening treated with, 129–142
 polishing of, 139, 186
 porcelain, 43
 prepress contact lenses and
 case study of, 234–245
 comparisons between, 43, 44t
 primary anatomy refinement, 102, 103f, 161, 165
 removal of, 138, 182, 238
 short teeth and deficient direct composite resin
 restorations with NCCLs treated with, 78–85
 show-through in, 92
 silver powder or glitter over, 102, 103f
 survival rates of, 127
 thickness of, 92
 with tooth preparation
 adequacy of, 180
 adhesive protocol for bonding, 183–186
 description of, 96
 design of, 128
 for discolored teeth, 127–128, 143–168
 factors that affect, 143
 guidelines for, 143–168
 incisal reduction in, 143
 need for, 127–128
 restoration treatment, 183
 tooth surface treatment, 183
 transitional line angles for, 98
- Type 1
 case study of, 78–85
 cervical chamfer in, 144
 characteristics of, 77
 discolored maxillary right central incisor treated with,
 145–151
 indications for, 144
 layering sequence for, 182
 tooth preparation for, 144–151
 Type 2 veneer versus, 86
- Type 2
 case study of, 87–91
 characteristics of, 86
 discolored maxillary left central incisor treated with,
 153–168
 layering sequence for, 182
 tooth preparation for, 152–168
 Type 1 veneer versus, 86
- VITA systems, 26, 29–30, 258
- VITA-based shades, 27
- W**
- Wavelength, of light-curing units, 8
- White, 37f–38f
- White spots, 159
- Working models, for indirect restorations, 217–218, 225
- Y**
- Yellow, 35, 36f, 38f