

Copyright
Not for publication
Quintessence



*N.M. Lopez
L. Siles Navilla*

Sillas Duarte, Jr, DDS, MS, PhD
Editor-in-Chief

2021/2022

QDT

QUINTESSENCE OF DENTAL TECHNOLOGY

Looking Ahead and Moving Forward



Last year, the world—and more specifically, the world of education—was turned upside down. With the need to socially distance and the fear of virus spread, online learning became essential for education to continue and for life to move forward.

Different types of remote learning were now part of our vocabulary: Zoom lectures, lives, distance learning, online education, etc. Synchronous and asynchronous learning would be the technical jargon for these new educational approaches. In the past, synchronous was synonymous with traditional education, where physical presence and brick-and-mortar facilities were necessary. However, with the pandemic this definition has expanded, and synchronous learning now involves all individuals meeting at a specific time, either physically or over a variety of electronic media, platforms, and technologies, but more importantly, happening in real time. This provides the opportunity for knowledge or ideas to be discussed, experiences to be shared, as well as questions to be answered concurrently. Conversely, in asynchronous learning, individuals have the flexibility to cover different learning resources at their own time and pace. Asynchronous learning methods include email, discussion boards, blogs, social networking, and streaming audio or video. If done properly, asynchronous learning allows improved cognitive participation and processing of information, since the learning material can be reviewed in several different ways. However, asynchronous learning lacks immediacy and may generate a sense of isolation.

Both synchronous and asynchronous learning require self-directed independent learning, which can be a real challenge. Most of us have observed our children and students in some sort of synchronous and/or asynchronous eLearning placement and experienced their and our own struggles with remote online learning. For self-directed independent learning to be effective, it requires self-discipline, focus, and interest—and these are the most difficult issues to overcome.

In dentistry, new teaching and learning modalities have proved to be effective, especially when combined with different methods of hand skills training and skills development. The latter may pose a challenge during these difficult times, since facilities, instruments, and equipment are still necessary, but it is far from being an impossible task. Different entities, such as the Centers for Disease Control and Prevention (CDC), have developed and continue to modify recommendations for safety. Education has changed forever, and luckily, we are now understanding what does and does not work for ourselves, our children, and for our students. Most importantly, we are understanding how to provide all with a plethora of opportunities to enhance knowledge and skills, but in our own individual way.

One of the biggest challenges in written communication is how to clearly describe in words all the steps required for a given procedure. Our QDT team spends many hours working with our authors to best present their accomplishments. But how many times you have read an article and asked yourselves, “If I could only see how it was done . . .” With this in mind, I take great pleasure in announcing that the *Quintessence of Dental Technology* has again pushed the boundaries of written communication by providing our readers with a multimedia eLearning opportunity. We have embraced the asynchronous eLearning, and in selected articles you can find a QR code that will take you to remarkably executed, step-by-step videos detailing the different techniques proposed.

I want to sincerely thank all authors who have worked with us throughout the pandemic for their amazing contribution to the dental community. A new standard for dental literature has been set. If you want to be part of it, I welcome you to join us!

Sillas Duarte, Jr, DDS, MS, PhD
sillas.duarte@usc.edu



QUINTESSENCE OF DENTAL TECHNOLOGY

EDITOR-IN-CHIEF

Sillas Duarte, Jr, DDS, MS, PhD
Associate Professor and Chair
Division of Restorative Sciences
Herman Ostrow School of Dentistry
University of Southern California
Los Angeles, California

ASSOCIATE EDITOR

Jin-Ho Phark, DDS, Dr MED Dent
University of Southern California
Los Angeles, California

EDITORIAL REVIEW BOARD

Pinhas Adar, CDT, MDT
Atlanta, Georgia

Naoki Aiba, CDT
Monterey, California

Oswaldo Scopin de Andrade, DDS,
MS, PhD
São Paulo, Brazil

Markus B. Blatz, DMD, PhD
Philadelphia, Pennsylvania

Ana Carolina Botta, DDS, MS, PhD
Stony Brook, New York

Sara Casado, DMD, MS
Lisbon, Portugal

Gerard J. Chiche, DDS
Augusta, Georgia

Shiro Kamachi, DMD
Boston, Massachusetts

Andrés Sánchez Monescillo, DDS, MS, PhD
Madrid, Spain

Luana Oliveira-Haas, DDS, MS, PhD
Lincoln, Nebraska

Avishai Sadan, DMD, MBA
Los Angeles, California

Thomas J. Salinas, DDS
Rochester, Minnesota

Eric Van Dooren, DDS
Antwerp, Belgium

Fabiana Varjão, DDS, MS, PhD
Los Angeles, California

Aki Yoshida, CDT
Weston, Massachusetts

EDITORIAL

Looking Ahead and Moving Forward

Sillas Duarte, Jr

3

MASTERPIECE

Healing Guided by Design: The Crown-Lengthening Procedure Revisited

Eric Van Dooren/Florin Cofar/Ioana Popp/Ioan Cofar/Marcelo Giordani/
Gustavo Giordani/Victor Clavijo

6

MASTERCLASS

RepliCAD—Digital Impression Strategies to Replicate the Soft Tissue Architecture and Teeth Position for Predictability in Final Restorations

Victor Clavijo/Ricardo Recena/Paulo Fernando Mesquita de Carvalho/
Willy Clavijo/Leonardo Bocabella

20

BIOMATERIALS UPDATE

Gradient Multilayered Zirconia

Sillas Duarte, Jr/Victor Clavijo/Willy Clavijo/Jin-Ho Phark

46

MASTERPIECE

The Modified All-On-4 Concept: Keeping Teeth for Lip Support and to Maintain Patients' Identity

Iñaki Gamborena/Yoshihiro Sasaki/Markus B. Blatz

60

Library-Based Design: Workflow and Bottlenecks

Florin Cofar/Ioan Barbur/Gustavo Giordani/Marcelo Giordani/Ioan Cofar/
Eric Van Dooren/Ioana Popp/Paul Ficut

74

Minimally Invasive Esthetic Approach in Full-Mouth Rehabilitation: Combining a Digital Workflow Using Intraoral and Facial Scanners

Anabell Bologna/Rafael Laplana

88

"Teamwork"

Cover photo by Andrés Sánchez Monescillo
Dental Technician: Nik Morozov



MASTERCLASS

Push the Limits: Porcelain Laminate Veneer Preparation for Intraoral Scanning 114
Masayuki Okawa/Akikazu Shinya/Shogo Yamamoto

The Digital Alveolar Support Technique: Use of Natural Shape to Design the Soft Tissue 144
Florin Cofar/Ioan Barbur/Gustavo Giordani/Marcelo Giordani/Ioan Cofar/
Eric Van Dooren/Ioana Popp/Paul Ficut

Virtual Dentoalveolar Clone Concept in the Esthetic Zone: Volumetric Assessment of Tissue Changes 160
Ivan Contreras Molina/Diego Michel A. Castillo Saucedo/
Kyle Stanley/Gil Contreras Molina

The 4_Spheres Technique 186
Mariano Maurizi

Restoration of Endodontically Treated Teeth: Classification of Remaining Dental Structure for Adhesive Restorative Procedures 194
Erika Clavijo/Victor Clavijo

The Double-Crown Technique for Masking Discoloration: Separating the Masking and Esthetic Parts of the Restoration 220
Aiham Farah/Anas Aloum

Digital Workflows to Optimize Peri-implant Soft Tissue Management: The Inverse Scan Body Concept 236
Oscar Gonzalez-Martín/Manuel Martín-Luque/
Andrés Acevedo/Gustavo Ávila-Ortiz

PUBLISHER

Christian W. Haase

PUBLISHER EMERITUS

H. W. Haase

EXECUTIVE VICE-PRESIDENT, DIRECTOR

William G. Hartman

JOURNAL DIRECTOR

Lori A. Bateman

PRODUCTION

Angelina Schmelter

ADVERTISING/EDITORIAL/ SUBSCRIPTION OFFICE

Quintessence Publishing Co, Inc
411 N Raddant Road
Batavia, Illinois 60510
Phone: (630) 736-3600
Toll-free: (800) 621-0387
Fax: (630) 736-3633
Email: service@quintbook.com
<http://www.quintpub.com>

QDT is published by
Quintessence Publishing Co, Inc,
411 N Raddant Road,
Batavia, Illinois, 60510.
Price per copy: \$165.

MANUSCRIPT SUBMISSION

QDT publishes original articles covering dental laboratory techniques and methods. For QDT submission information, contact the publisher (service@quintbook.com).

Copyright © 2022 by Quintessence Publishing Co, Inc. All rights reserved. No part of this publication may be reproduced or transmitted in any form or by any means, electronic or mechanical, including photocopying, recording, or any information and retrieval system, without permission in writing from the publisher. The publisher assumes no responsibility for unsolicited manuscripts. All opinions are those of the authors. Reprints of articles published in QDT can be obtained from the authors.

Permission to photocopy items solely for internal or personal use and for the internal or personal use of specific clients is granted by Quintessence Publishing Co, Inc, for libraries and other users registered with the Copyright Clearance Center (CCC) provided the appropriate fee is paid directly to CCC (www.copyright.com).

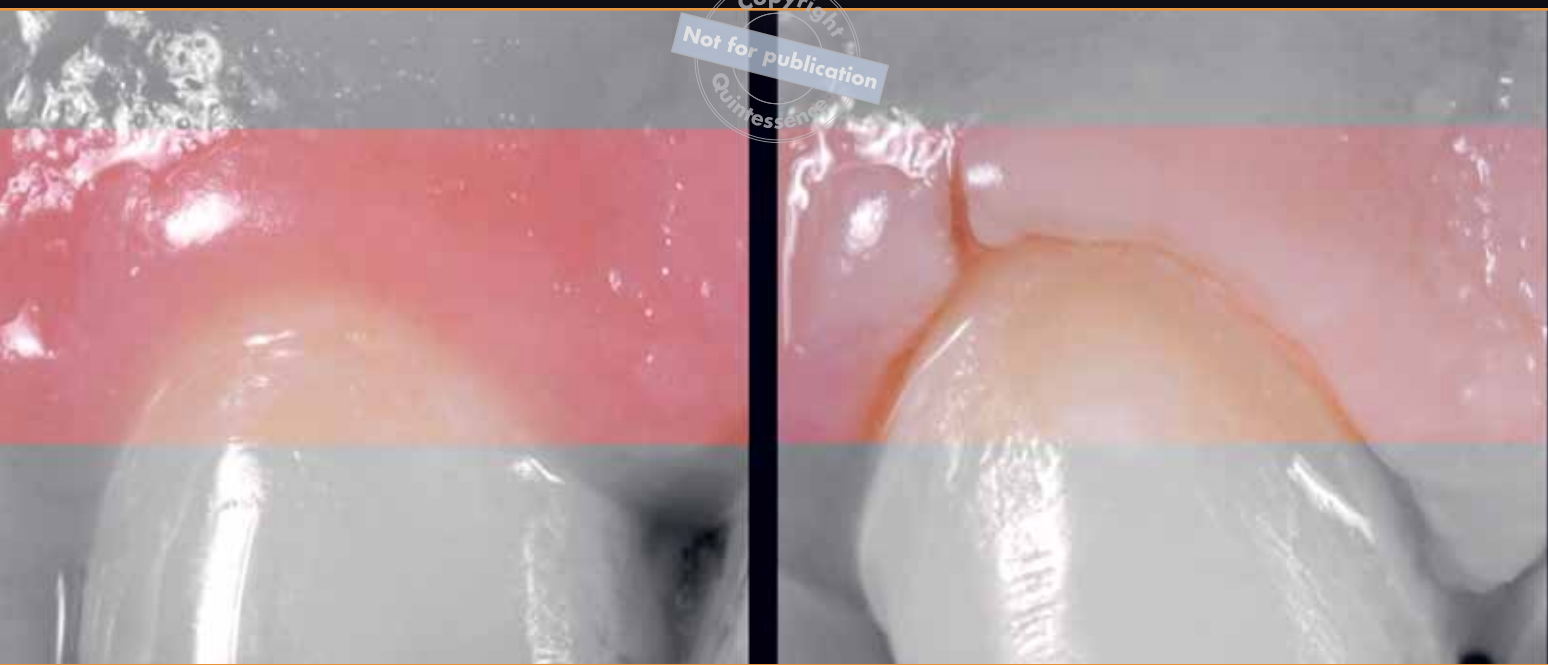
Printed in Croatia.

ISSN: 1060-1341 / ISBN 978-1-64724-103-2



Additional video content

Scan QR codes in selected articles to view video presentations of techniques.



Masterpiece

Healing Guided by Design: The Crown-Lengthening Procedure Revisited

Eric Van Dooren, DDS¹

Florin Cofar, DDS²

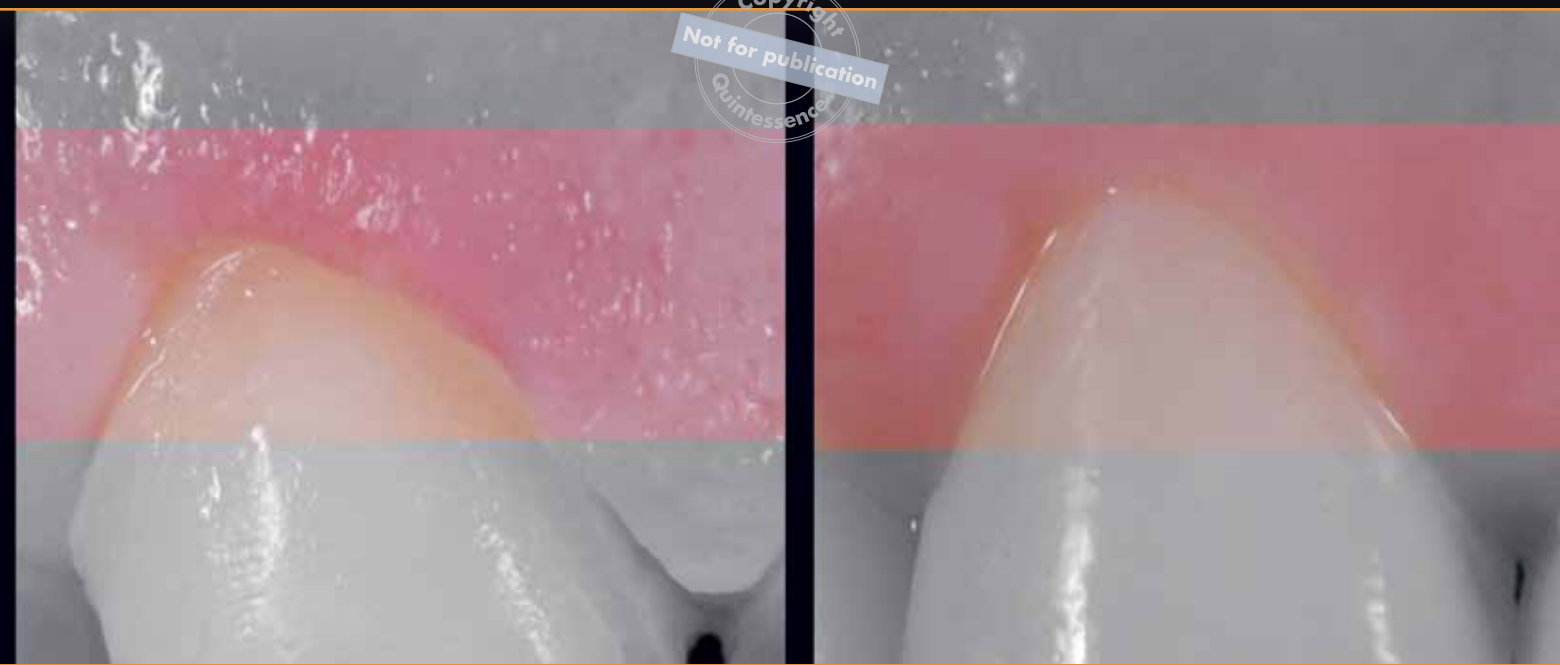Ioana Popp, CDT²

Ioan Cofar, DDS²

Marcelo Giordani, DDS³

Gustavo Giordani, DDS⁴

Victor Clavijo, DDS, MS, PhD⁵



The success of any anterior implant surgery comes partly from the surgical procedure and partly from the prosthetic design to support the tissue. This lesson learned from implant dentistry can be important in terms of rethinking how we manage natural teeth scenarios. Unlike implants, in which the provisional or final restorations are used to guide the soft tissue during healing, dental restorations are placed in fully healed periodontal tissues. This means that once a crown-lengthening

surgery is performed, it seldom has the final prosthetic restorative support—and no restorative guidance or limited provisional guidance. The final restoration is then fabricated after the periodontal healing phase. This reactive approach to tissue healing often leads to modifications in the restoration design to accommodate the changes that occurred during the healing process.

Due to advancements in digital dentistry, specifically in the speed of manufacturing and library-based design, which allow a more consistent and predictable fabrication of well-designed restorations, a new narrative is emerging: the use of digital design based on natural teeth morphology, similar to the way it currently is used for implant-supported restorations. Library-based design can be used to support and act as a scaffold of healing for both crown lengthening and grafting procedures. It allows less invasive crown-lengthening techniques.

The following case describes and illustrates an innovative crown-lengthening approach guided by the final restorative design for optimal healing of the periodontal tissues.

¹Private Practice limited to prosthodontics, implants, and periodontal plastic surgery, Antwerp, Belgium.

²DENTCOF, Timisoara, Romania.

³Alpha-Alpha Taboré Odontologia, São Paulo, Brazil.

⁴Studio Giordani, São Paulo, Brazil.

⁵Private Practice, Indaiatuba, Brazil; Visiting Professor, Advanced Program in Operative and Restorative Dentistry, Division of Restorative Sciences, Herman Ostrow School of Dentistry, University of Southern California, Los Angeles, California, USA.

Correspondence to: Dr Eric Van Dooren, Tavérnierkaai 2, 2000 Antwerp, Belgium. Email: vandoorendent@skynet.be

PATIENT PRESENTATION

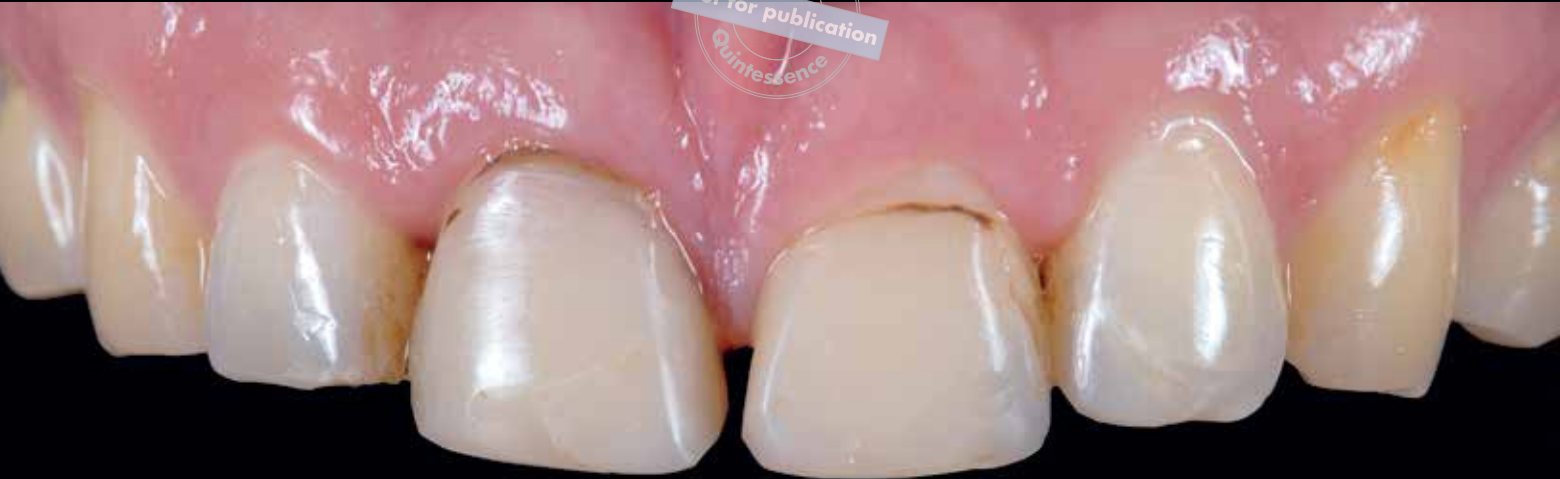

Fig 1 The patient presented with traumatized maxillary anterior dentition with fractures and cracks in addition to uneven gingival tissues.

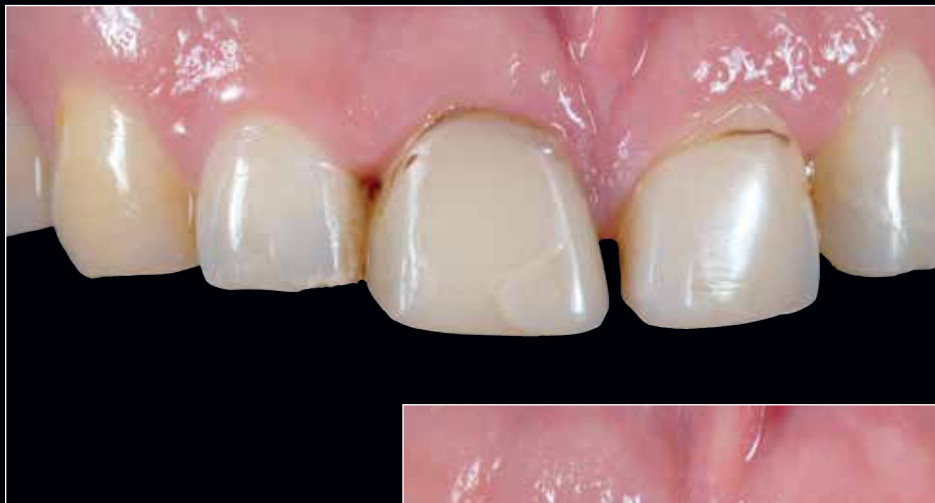
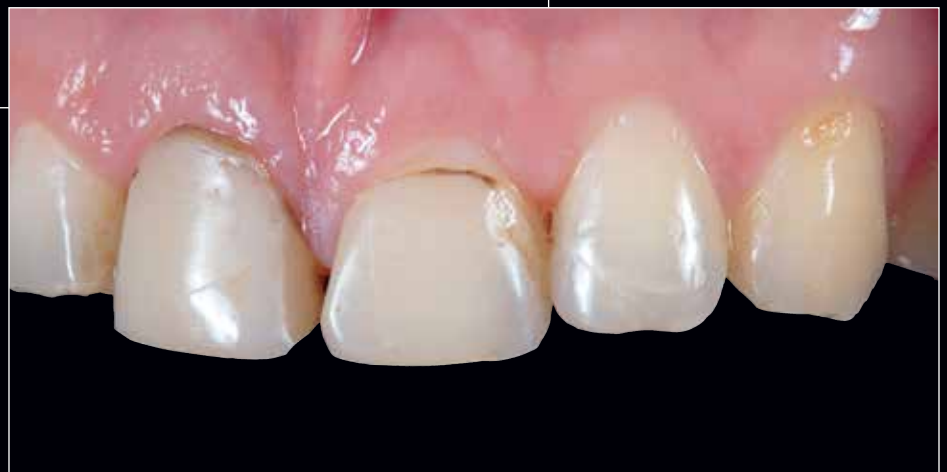
Fig 2 Left and right preoperative views. The maxillary central incisors previously suffered trauma and were restored with composite resin. The existing tooth shape is inadequate and crown length too short. To adequately restore the morphology of the maxillary anterior teeth, soft and hard tissue management was necessary.



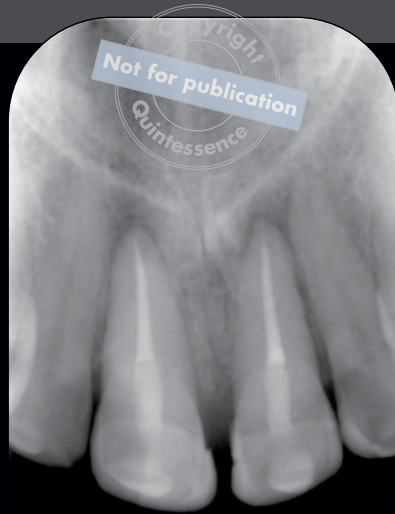


Fig 3 Endodontic treatment immediately after trauma (Dr Alexander Schryvers, Antwerp, Belgium).

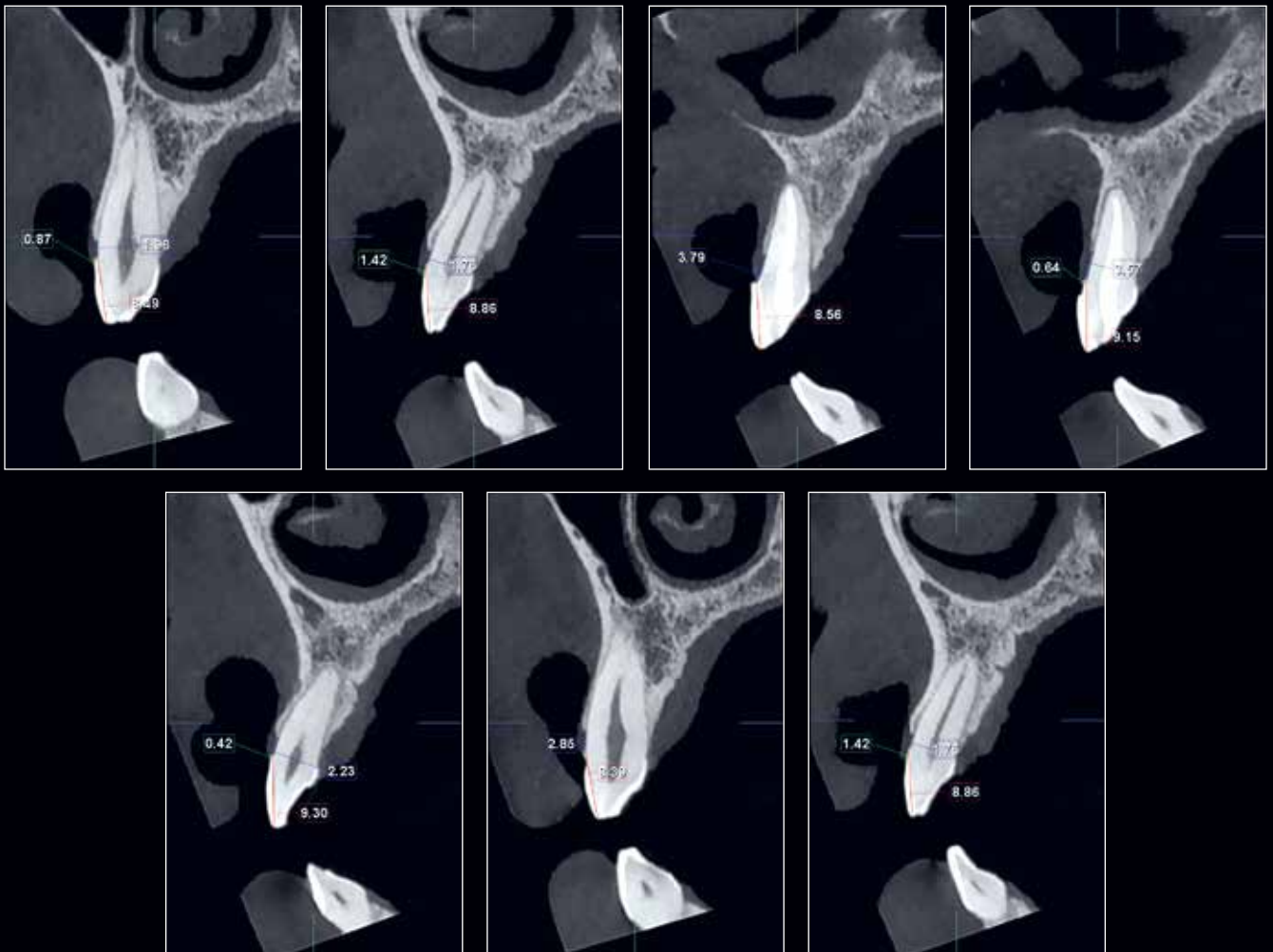


Fig 4 CBCT evaluation of the maxillary anterior teeth.

DIGITAL DESIGN

Design in Smilecloud is, in essence, an artificial intelligence (AI)-powered natural shapes search engine that is able to render unique compositions into virtual lifelike smile designs. It has a double value: (1) for communication with both the patient and the technician, acting like a visual order system, and (2) for searching shapes that match 3D without the need for extensive adjustments, thus maintaining natural morphology.

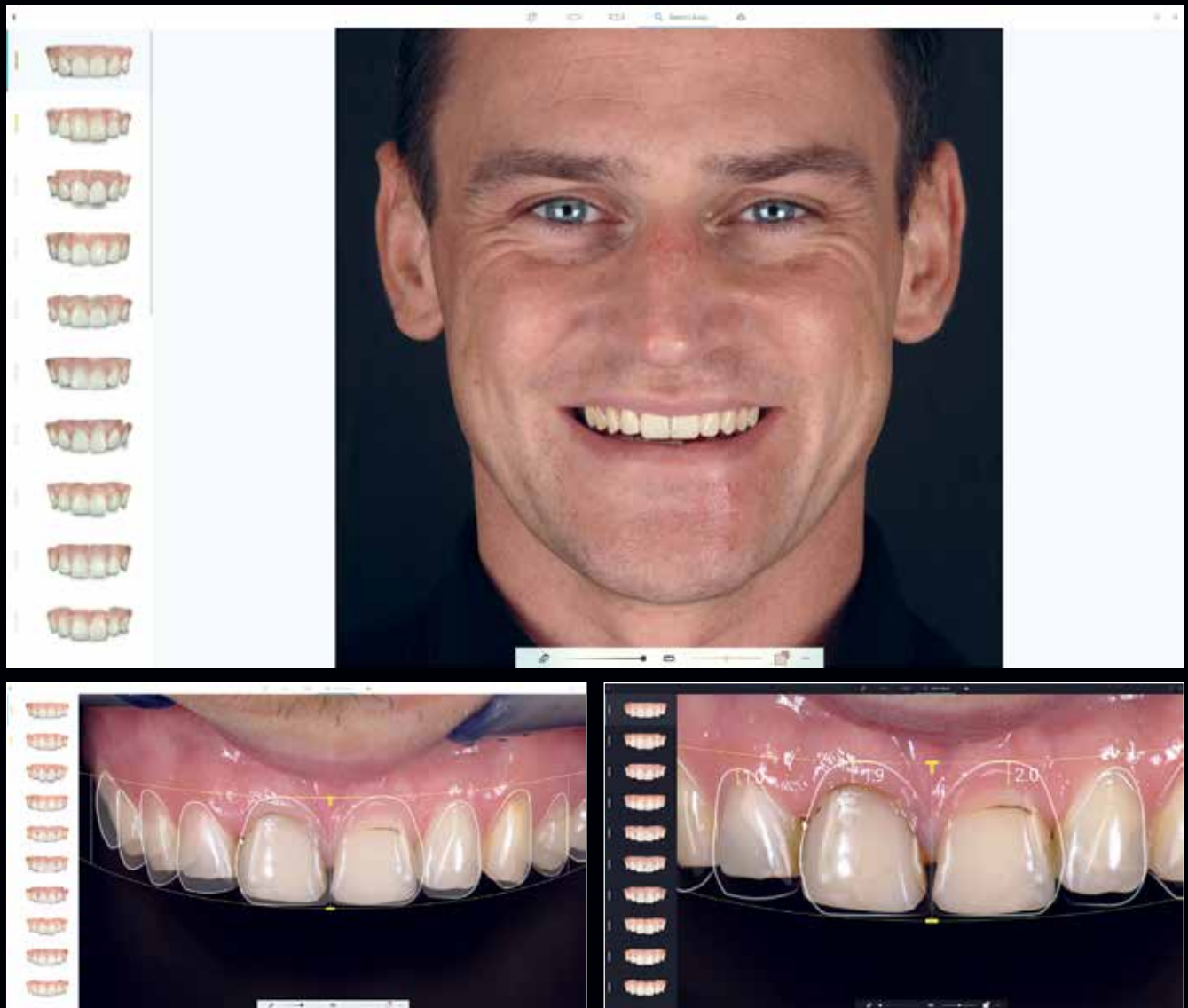


Fig 5 The patient's images were uploaded in a digital design tool (Smilecloud software, www.smilecloud.com). The evaluation of the ideal tooth shape for the maxillary anterior teeth revealed the need for crown lengthening, but more specifically provided the amount of crown lengthening required for each tooth. The algorithm in the software uses a selection of natural tooth forms, and the goal during treatment was to keep the natural tooth forms selected by the algorithm for all maxillary anterior teeth to serve as a guide for both clinical crown lengthening and prosthetic design. This reverse planning allowed for precise, fast, and predictable treatment. The final goal was to complete the treatment—from initial documentation to bonding of the final restorations—within 5 business days.

CROWN LENGTHENING

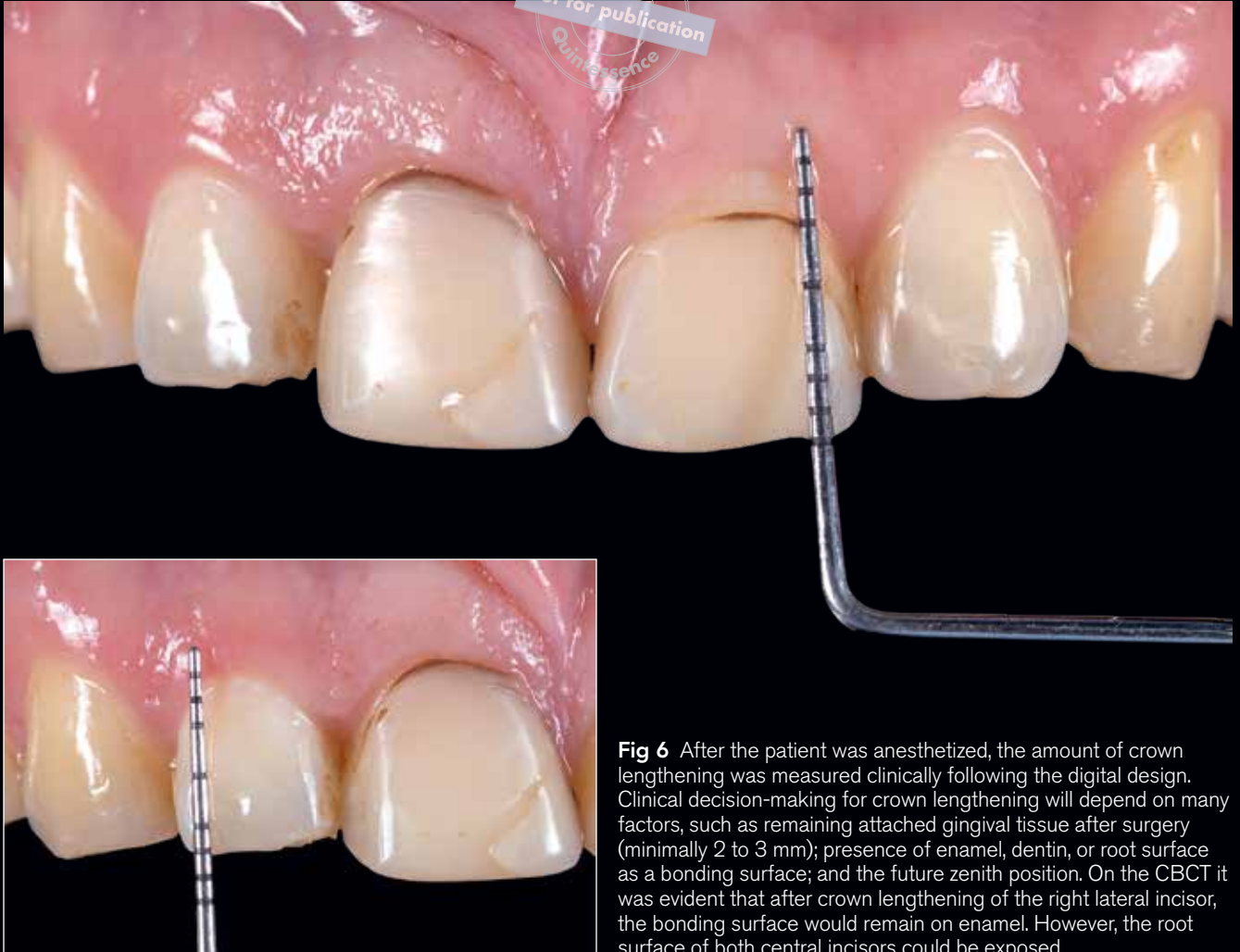


Fig 6 After the patient was anesthetized, the amount of crown lengthening was measured clinically following the digital design. Clinical decision-making for crown lengthening will depend on many factors, such as remaining attached gingival tissue after surgery (minimally 2 to 3 mm); presence of enamel, dentin, or root surface as a bonding surface; and the future zenith position. On the CBCT it was evident that after crown lengthening of the right lateral incisor, the bonding surface would remain on enamel. However, the root surface of both central incisors could be exposed.

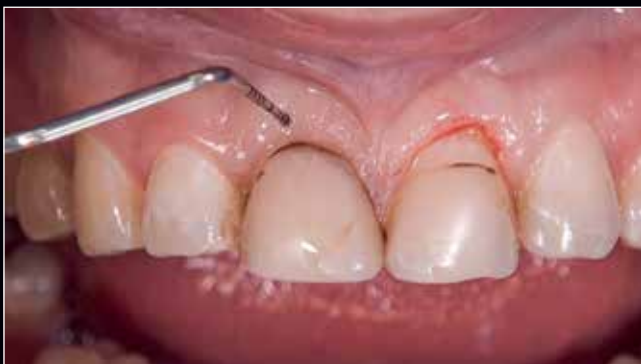

Fig 7a For the two central incisors, a probing perforation was done at the new zenith level.

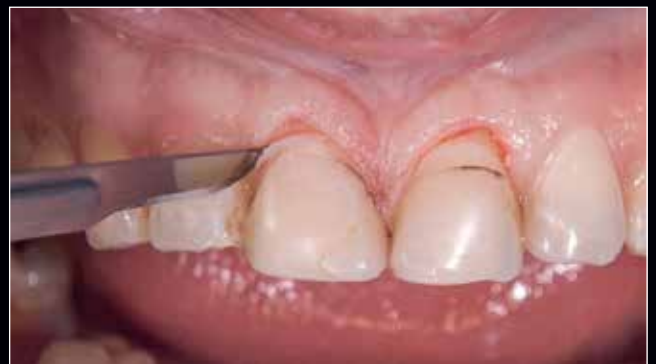
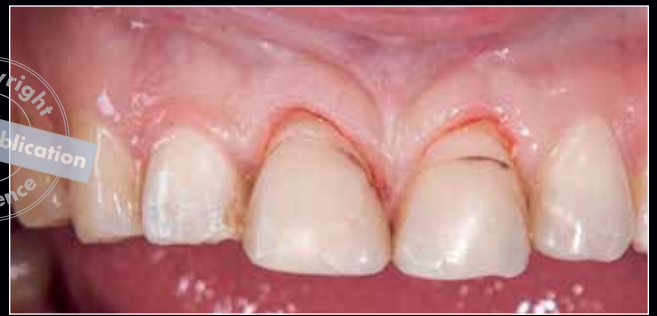
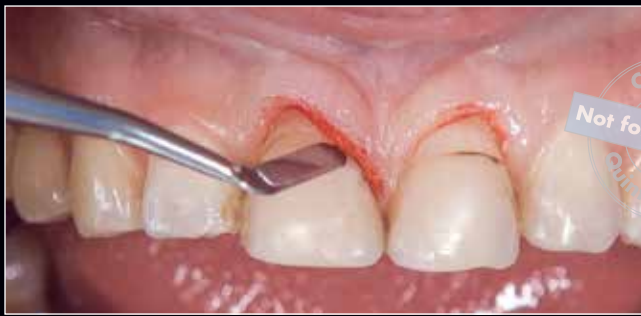Fig 7b Gingivectomy was accomplished with an internal beveled incision (no. 15 scalpel) performed at the facial aspect of the involved teeth and following the digitally designed gingival contour to create a new gingival zenith and outline.



Figs 7c and 7d Thick retraction cord is used to displace the gingiva and form the new gingival contour.

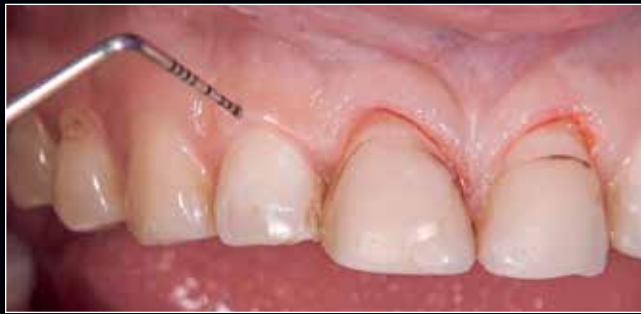

Fig 7e Probing is also performed on the right lateral incisor. For this tooth specifically, the new approach will be used.

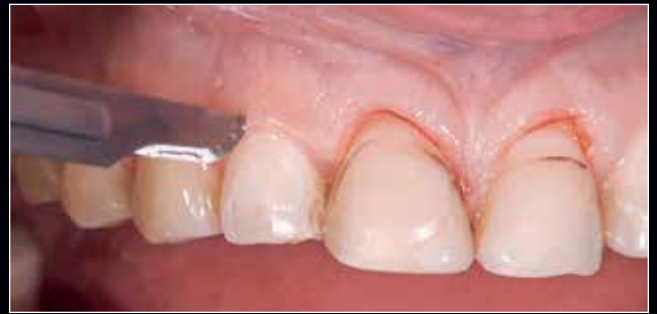

Fig 7f The technique involves using a releasing incision to connect the existing zenith with the future zenith, followed by flapless bone recontouring. This technique can be used up to a maximum of 1.5 mm.

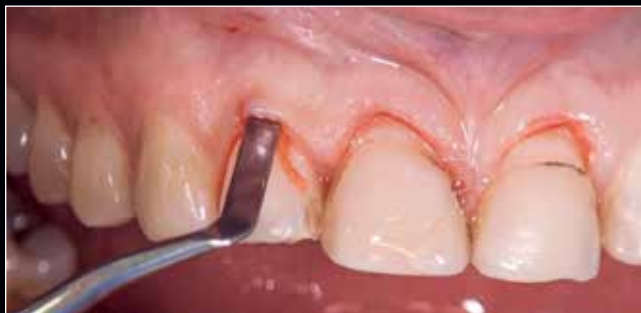

Fig 7g Thick retraction cord (Pascal #9) is used to displace the tissue and allow the operator to achieve the preparation finishing margin location according to the digital design.

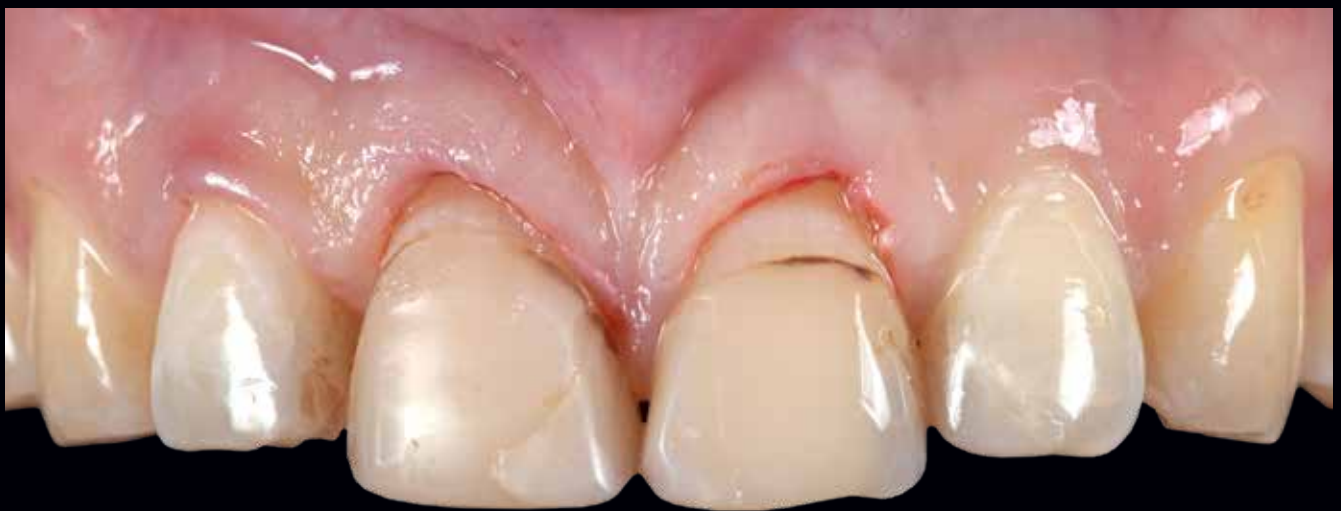

Fig 8 Frontal view after clinical crown lengthening with retraction cords in place and before initial preparation. Note the immediate improvement of the gingival architecture and teeth proportions.

TEETH PREPARATION

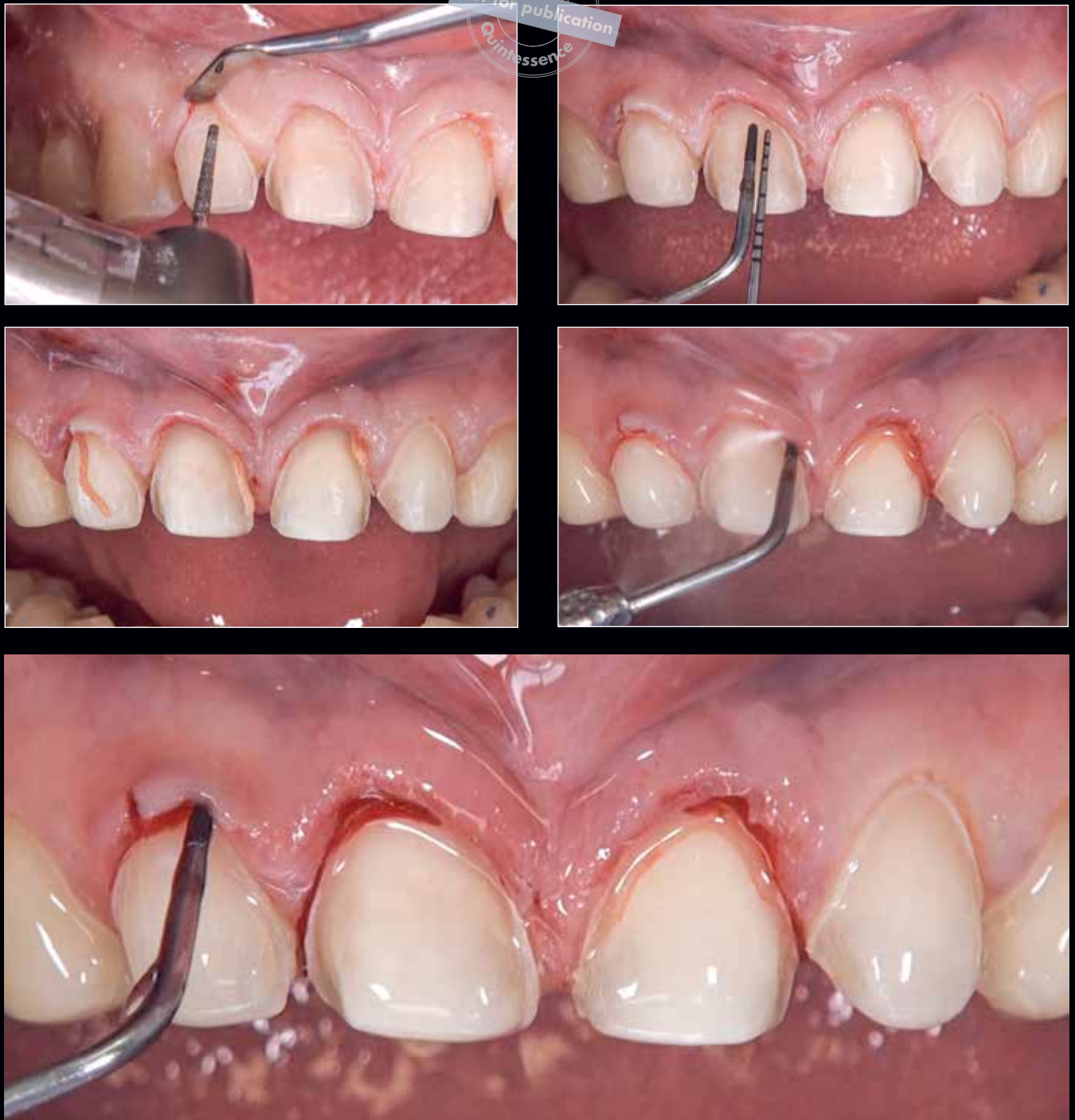

Fig 9 Preparation finishing margins should follow the library design and not the displaced soft tissue. When the provisional or final restoration is in place, the displaced tissue will migrate interproximally, allowing for a better papillae/gingival line angle relationship from a sagittal perspective and papillae/contact area relationship from a frontal perspective.

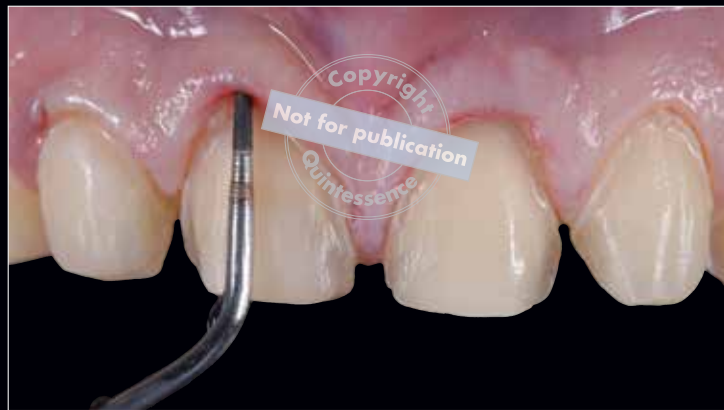

Fig 10 After final preparation, the new biologic width was restored by osteotomy and osteoplasty using a piezoelectric device (CVDentus, CVD Vale). This procedure is done in a flapless, atraumatic, and non-invasive way as possible in order to have minimal trauma and fast healing. A distance of 3.0 mm between the bone crest and cemento-enamel junction (CEJ) was obtained.

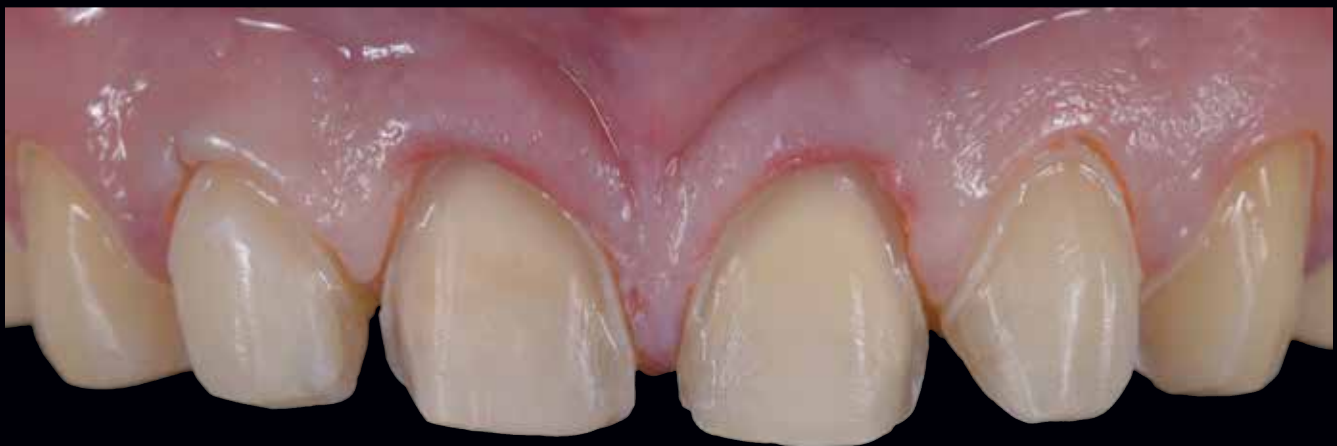

Fig 11 Final preparations with retraction cords in place and after the design-guided crown-lengthening procedure. During the preparation it is important to keep the finishing margins supragingival at the mesial and distal line angles of the preparation; the zenith is the only area that should be intrasulcular. This will maintain the integrity of the soft tissue and papillae. Both digital and polyvinyl siloxane impressions were made.

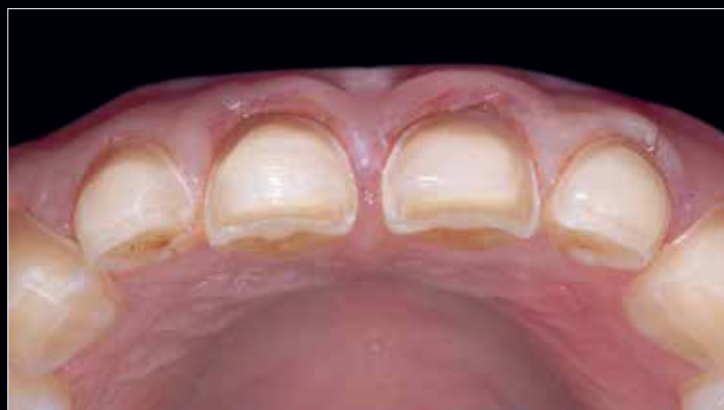

Fig 12 Occlusal view of the final preparations. Note the difference between the central incisors with gingivectomy and the right lateral incisor with the minimal vertical incision.

FABRICATION OF RESTORATIONS

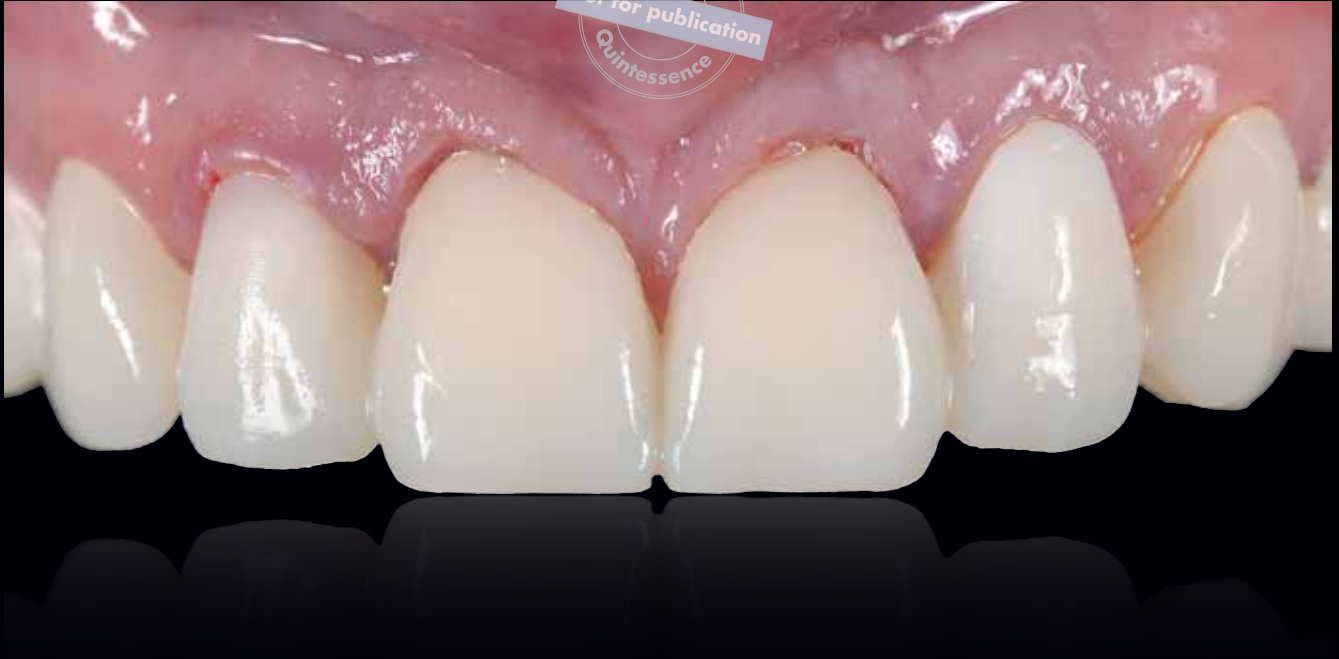

Fig 13 Provisional restorations based on the design were fabricated to keep the gingival tissue at the expected location and allow for initial healing. The patient is asked to brush with high concentration of active oxygen gel (Blue M, Blue M Care) at the restorative-periodontal interface. Note the color difference between the central and lateral incisors as a result of the difference in material thickness and substrate shade. The slight discoloration of the teeth needs to be addressed when fabricating the monolithic restorations.

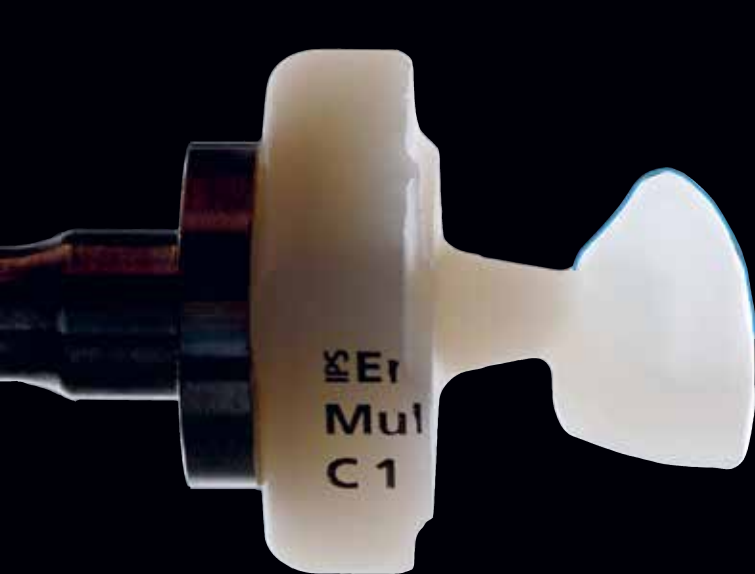


Fig 14 Using the initial design, leucite-reinforced glass-ceramic veneers were milled (Empress CAD Multi, Ivoclar Vivadent). Note the gingival contour of the right lateral incisor veneer (*highlighted in blue*). The details and precision of the milling following the initial digital design will condition the healing and positioning of the marginal soft tissue after bonding.



Fig 15 Monolithic CAD/CAM restorations were finished, stained, and polished.

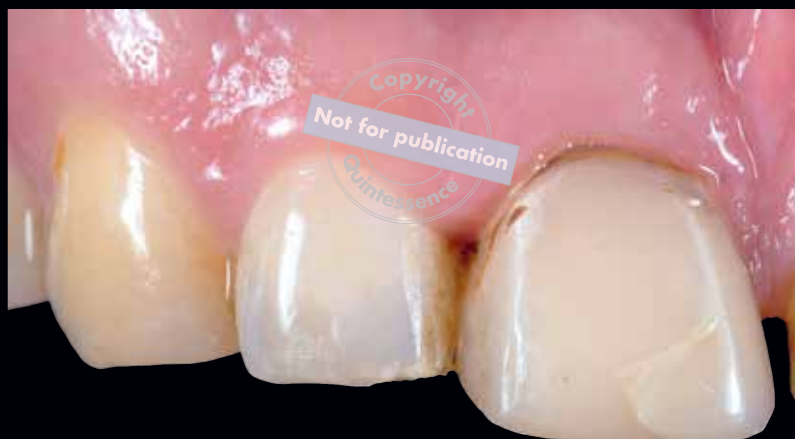

Fig 16a Preoperative situation of right lateral incisor.

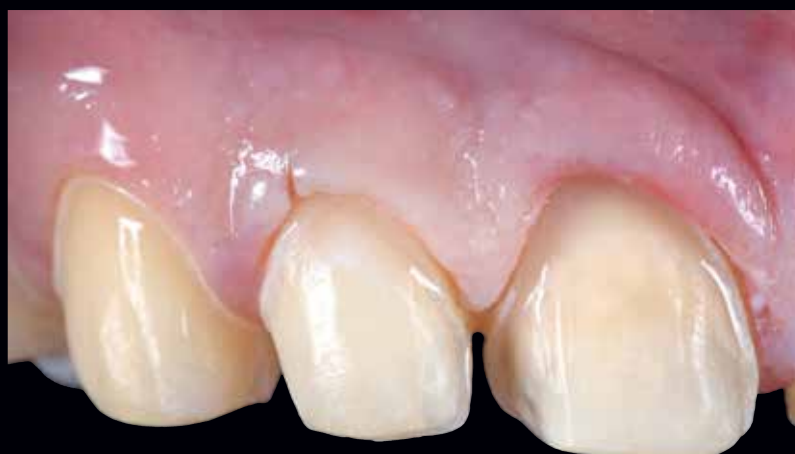

Fig 16b Day 1: Crown lengthening (incision with flapless osseous correction) and preparation.

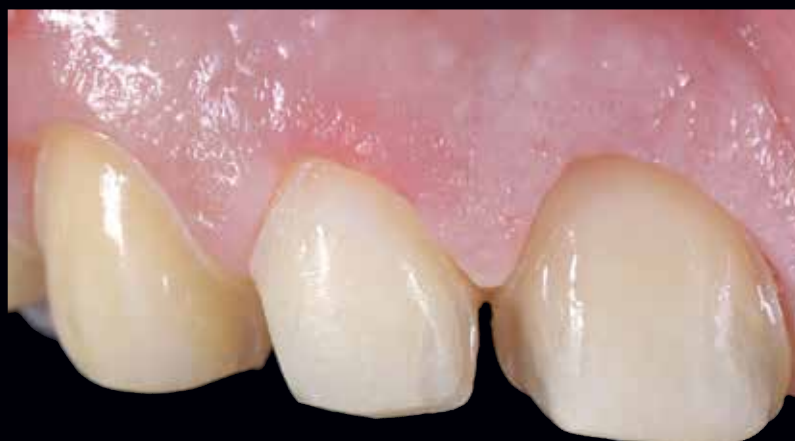

Fig 16c Day 4: Initial healing of soft tissue and after removal of the provisional bridge before bonding.

RESTORATION DELIVERY

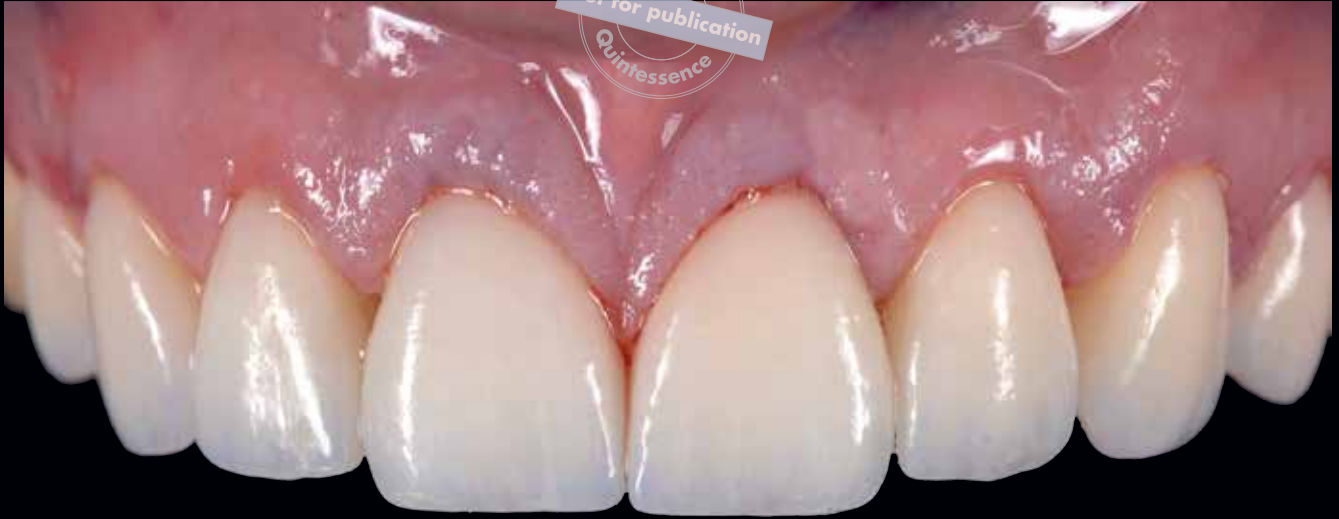

Fig 17a Three days after crown lengthening and tooth preparation, the restorations were delivered.

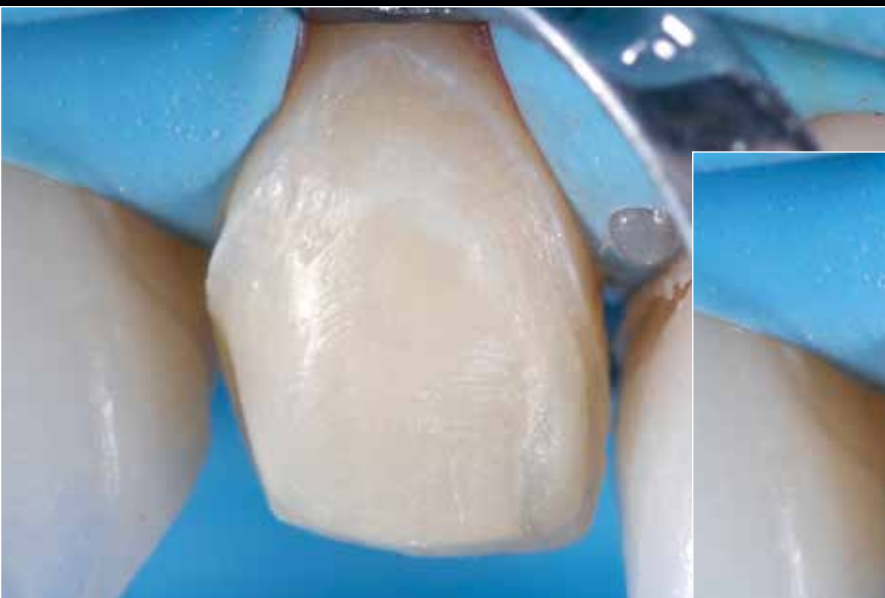

Fig 17b Rubber dam isolation was used for bonding of the restorations. Note the veneer preparation design under the rubber dam.

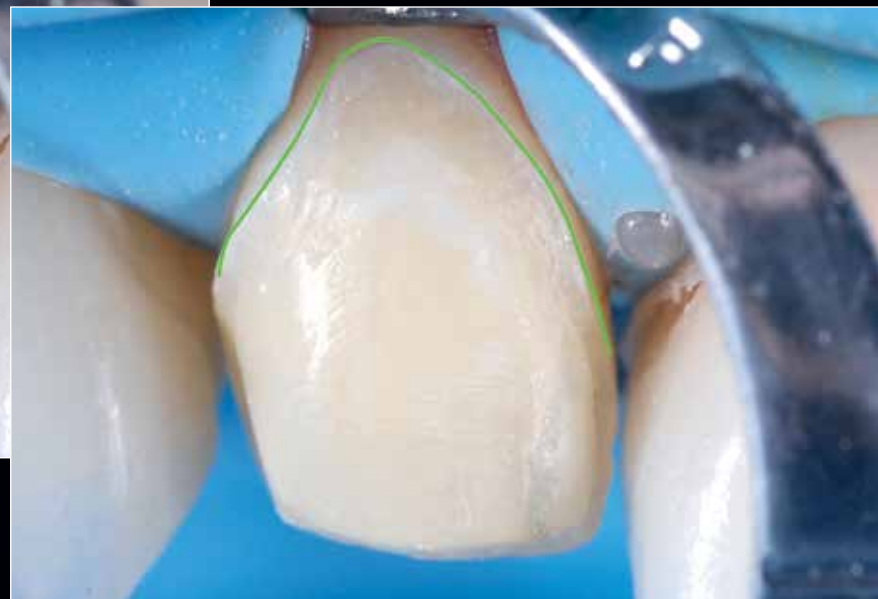

Fig 17c The mesial and distal line angles should be placed supragingivally, whereas the zenith can be located intrasulcular (*green line*). The use of rubber dam is mandatory to avoid any contamination during bonding procedures and to facilitate cleaning of the margins.

TISSUE HEALING

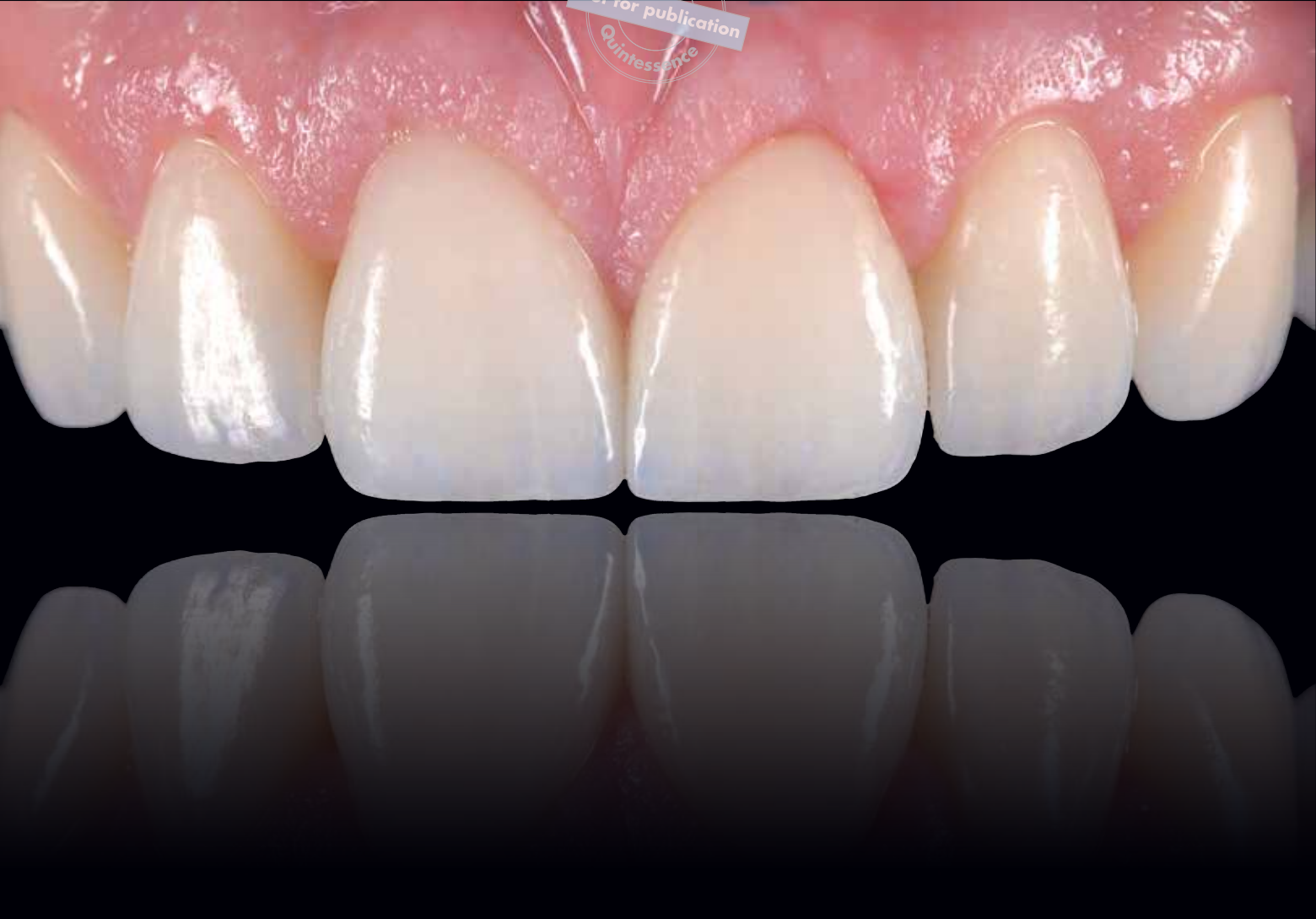

Fig 18 Healing of periodontal tissues 4 days after delivery. The initial healing will be guided by the initial digital natural tooth form from the digital library. That is why the bonding of the final restorations should be done within a week after clinical crown lengthening and final preparation. The patient is asked to brush with a high concentration of active oxygen gel (Blue M, Blue M Care) immediately after bonding and to optimize oral hygiene especially at the interface between the veneer and gingival tissues.



View video of this crown-lengthening approach guided by design.

RESTORATIVE OUTCOME

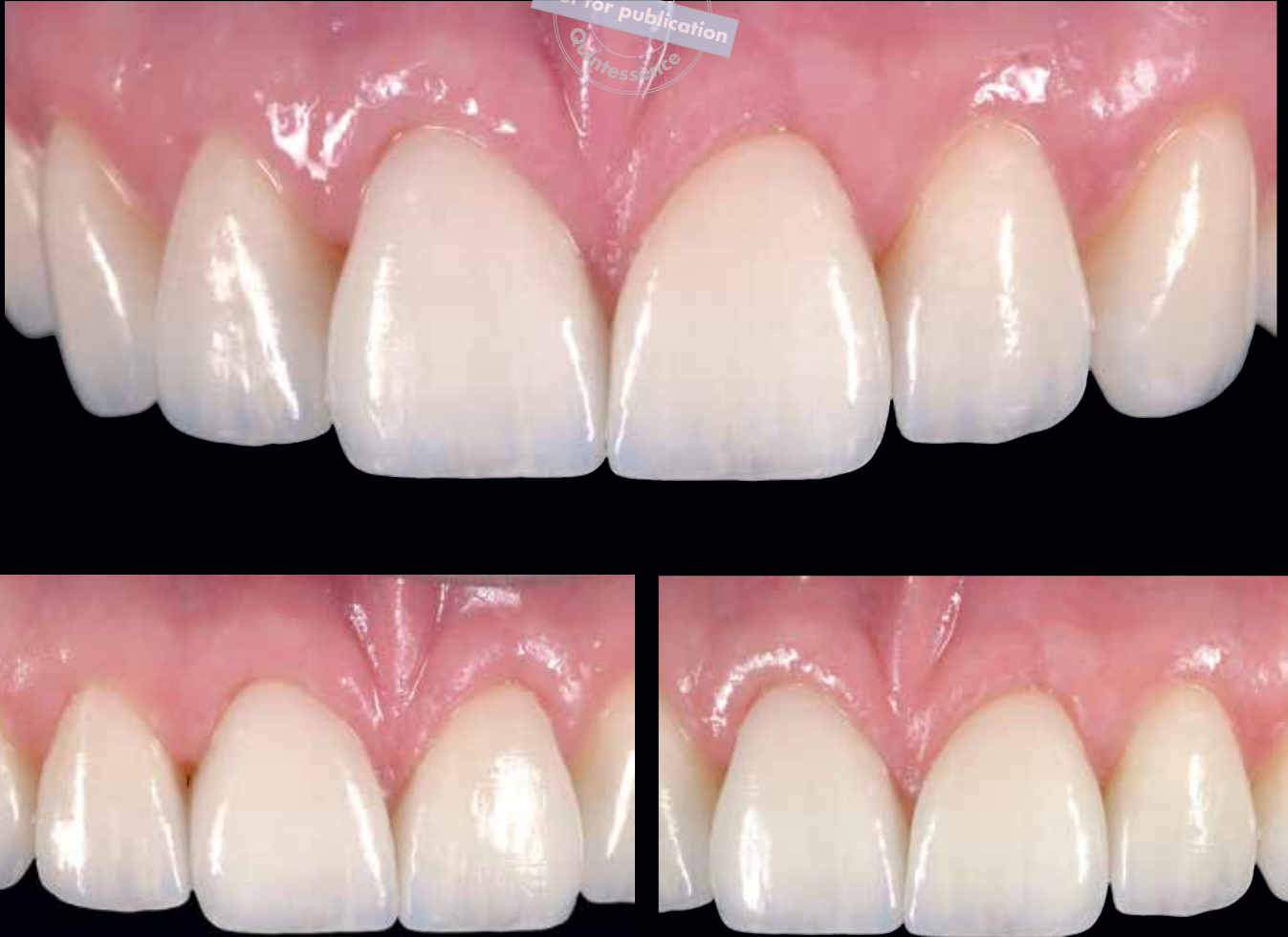

Fig 19 Final aspect after healing.

CONCLUSION

The new crown-lengthening approach guided by design provides patients with a minimally invasive and fast procedure with optimal healing. Traditional gingivectomy and soft tissue resecting techniques expose a thicker portion of the

subular epithelium that upon healing produces a shadow effect at the gingival interface of the restoration due to its thickness. Healing guided by design results in minimal soft tissue modification. Thus, by maintaining the transitional tissue in its original thickness, no thickening of the gingival tissues occurs, producing a more natural esthetic outcome.