Sebastian Cotofana
Karl H. Wesker
Bernard C. Kolster

FACIAL ANATOMY

Layer by Layer

Copyrighted material © Quintessence Publishing

Copyrighted material © Quintessence Publishing

QUINTESSENCE PUBLISHING

Berlin | Chicago | Tokyo
Barcelona | London | Milan | Paris | Prague | Seoul | Warsaw
Beijing | Istanbul | Sao Paulo | Sydney | Zagreb

Table of Contents

1. Forehead

12 Overview
14 Facial aging process
15 Biomechanics
19 Anatomic layers
28 Neurovascular Structures

2. Temples

34 Overview
36 Facial aging process
37 Biomechanics
40 Anatomic layers
49 Neurovascular Structures

3. Glabella

56 Overview
58 Facial aging process
59 Biomechanics
66 Anatomic layers
72 Neurovascular Structures

4. Supraorbital

78 Overview
80 Facial aging process
81 Biomechanics
84 Anatomic layers
93 Neurovascular Structures

5. Infraorbital

98 Overview
100 Facial aging process
101 Biomechanics
104 Anatomic layers
115 Neurovascular Structures

6. Nose

120 Overview
122 Facial aging process
123 Biomechanics
128 Anatomic layers
138 Neurovascular Structures

7. Medial Middle Face

144 Overview
146 Facial aging process
147 Biomechanics
150 Anatomic layers
160 Neurovascular Structures

8. Lateral Middle Face

166 Overview
168 Facial aging process
169 Biomechanics
172 Anatomic layers
180 Neurovascular Structures

9. Lips

186 Overview
188 Facial aging process
189 Biomechanics
192 Anatomic layers
205 Neurovascular Structures

10. Chin

214 Overview
216 Facial aging process
217 Biomechanics
220 Anatomic layers
229 Neurovascular Structures

11. Jawline

234 Overview
236 Facial aging process
237 Biomechanics
240 Anatomic layers
249 Neurovascular Structures

12. Neck

254 Overview
256 Facial aging process
257 Biomechanics
260 Anatomic layers
267 Neurovascular Structures

13. Overview

274 Anatomic systems of the face

Appendix

294 References
299 Index

Copyrighted material © Quintessence Publishing

Copyrighted material © Quintessence Publishing

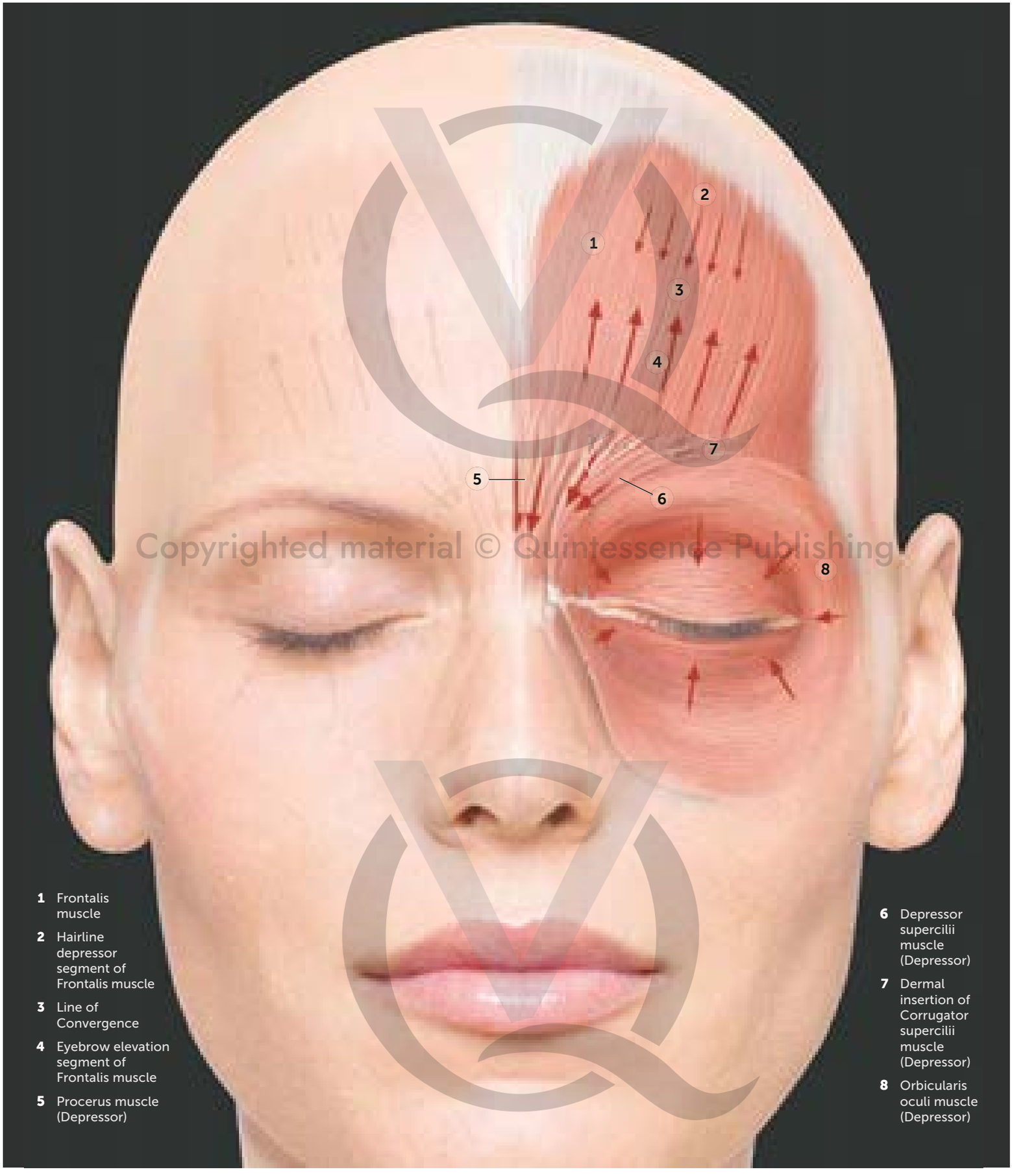

1 Frontalis muscle
2 Hairline depressor segment of Frontalis muscle
3 Line of Convergence
4 Eyebrow elevation segment of Frontalis muscle
5 Procerus muscle (Depressor)
6 Depressor supercilii muscle (Depressor)
7 Dermal insertion of Corrugator supercilii muscle (Depressor)
8 Orbicularis oculi muscle (Depressor)

Copyrighted material © Quintessence Publishing

3 Contraction direction of the muscles involved in eyebrow positioning.

Copyrighted material © Quintessence Publishing

Forehead: Anatomic Layers

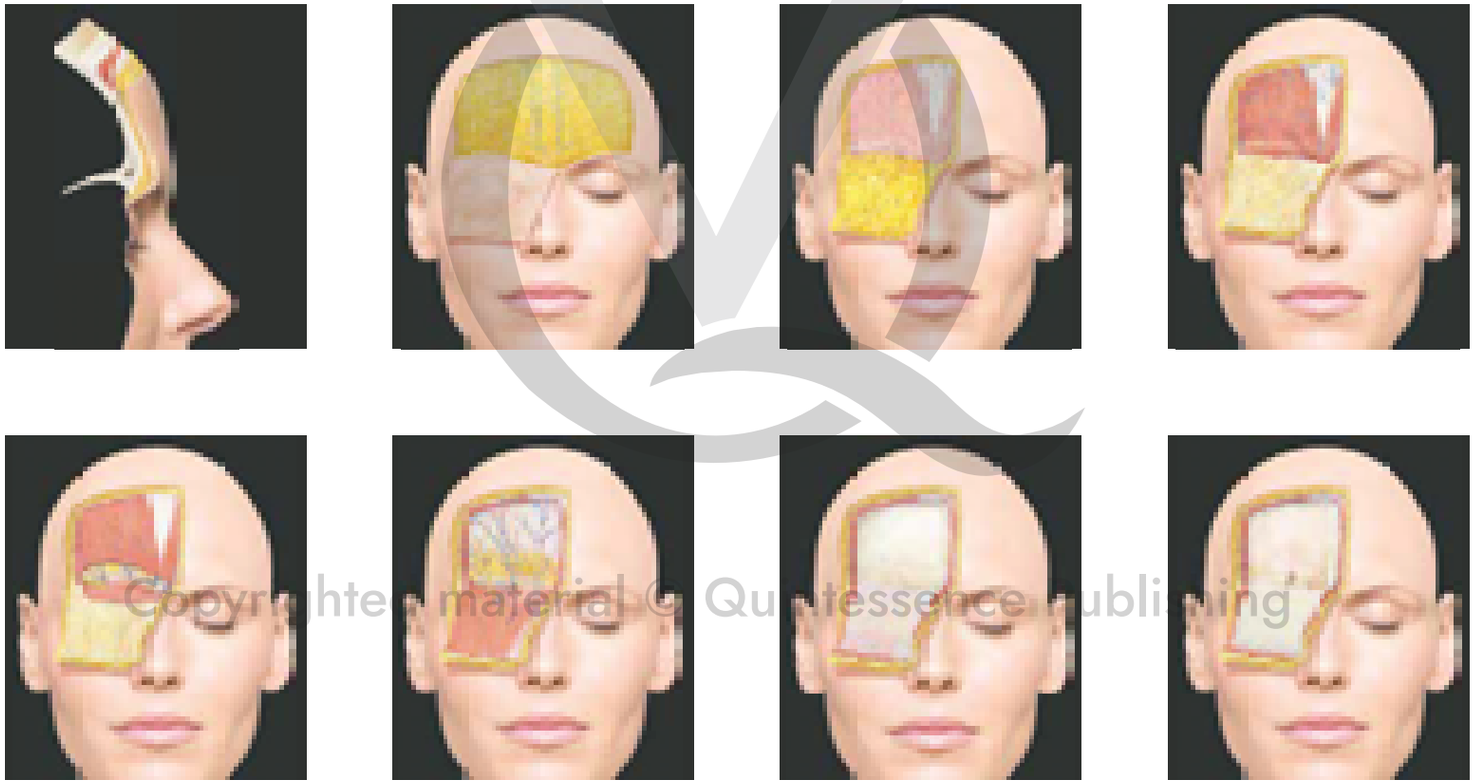

Copyrighted material © Quintessence Publishing

The forehead contains eight different fascial layers:

1. Skin
2. Superficial fatty layer (arranged in compartments)
3. Suprafrontalis fascia
4. Frontalis muscle
5. Retrofrontalis fatty layer (arranged in compartments)
6. Subfrontalis fascia
7. Loose connective tissue (arranged in compartments)
8. Periosteum

When tracing the five layers of the scalp into the forehead, it becomes evident that the galea aponeurotica separates into three distinct fascial layers:

1. Suprafrontalis fascia
2. Frontalis muscle
3. Subfrontalis fascia

This separation explains the pathway of the neurovascular structures as they emerge from their respective foramina and make their way cranially into the hair-bearing region of the head.

The subfrontalis fascia connects to the supraorbital periosteum, giving rise to the middle and inferior frontal septa; the space between these septa is termed the supraorbital ligamentous adhesion.

The inferior frontal septum forms the upper boundary of the corrugator supercilii muscle and serves as a protective membrane.

Copyrighted material © Quintessence Publishing

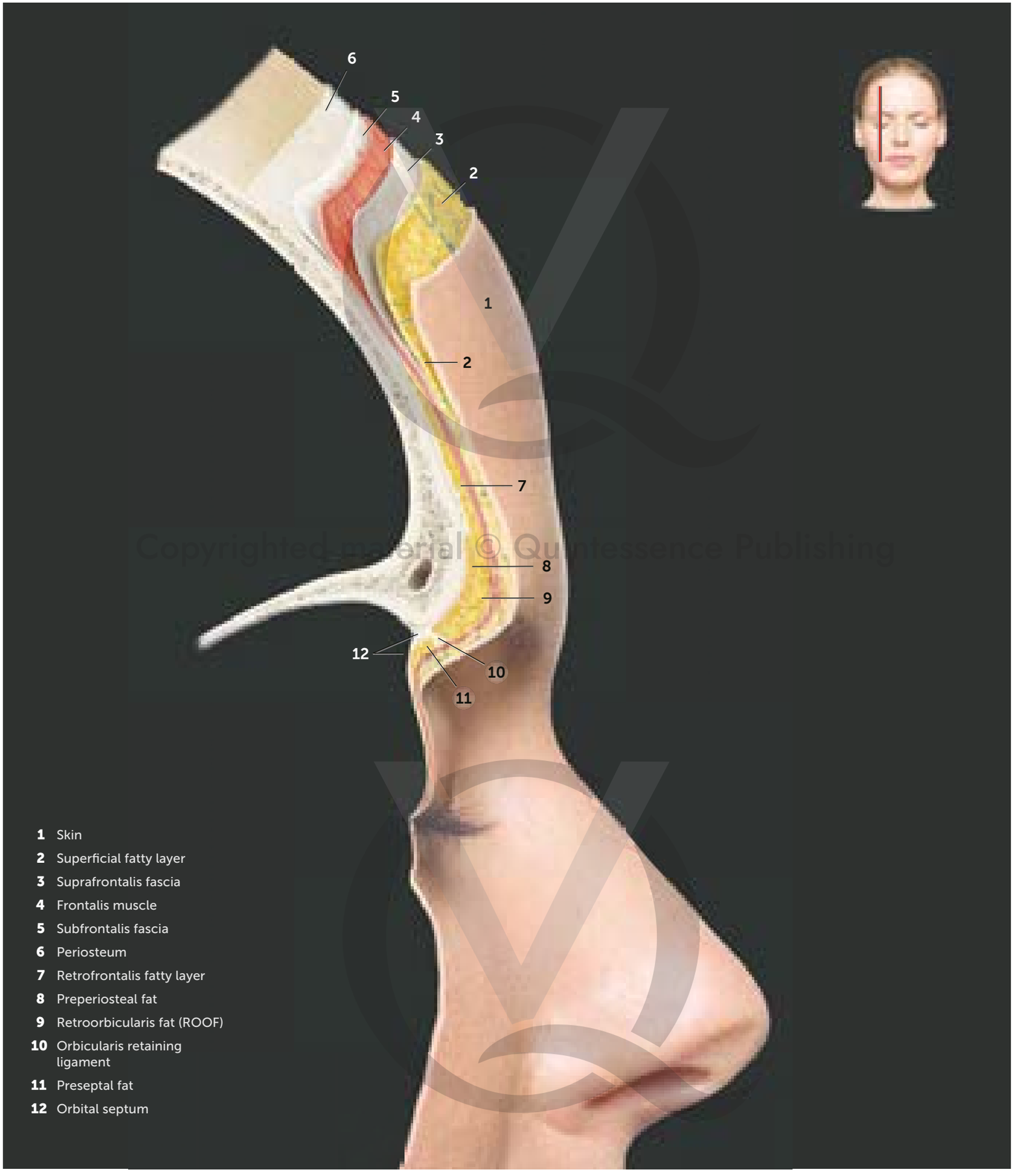

Copyrighted material © Quintessence Publishing

4 Layers of the frontal region in side view.

Copyrighted material © Quintessence Publishing

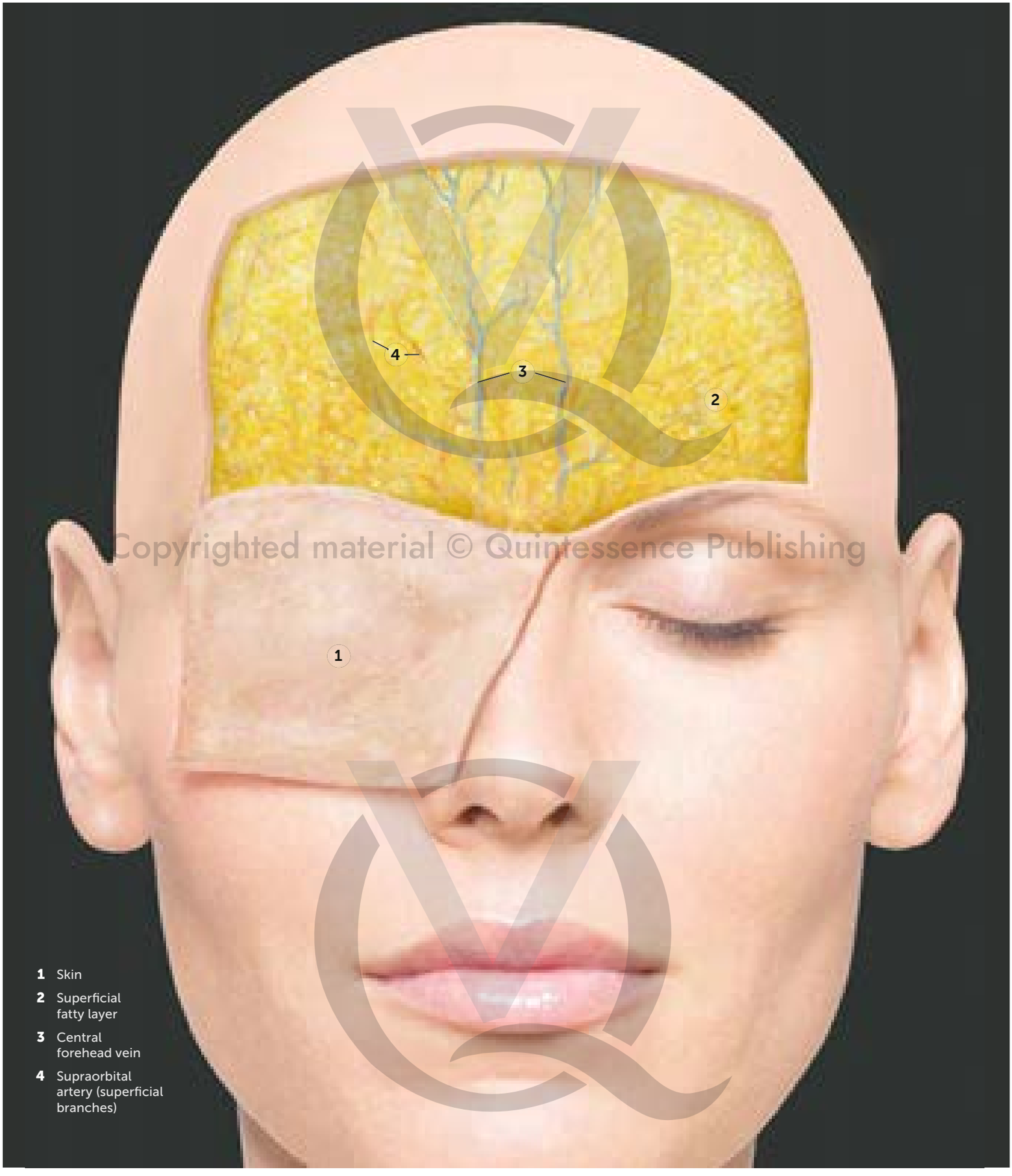

Copyrighted material © Quintessence Publishing

5 View of the superficial fatty layer (layer 2) after reflecting the skin.

Copyrighted material © Quintessence Publishing

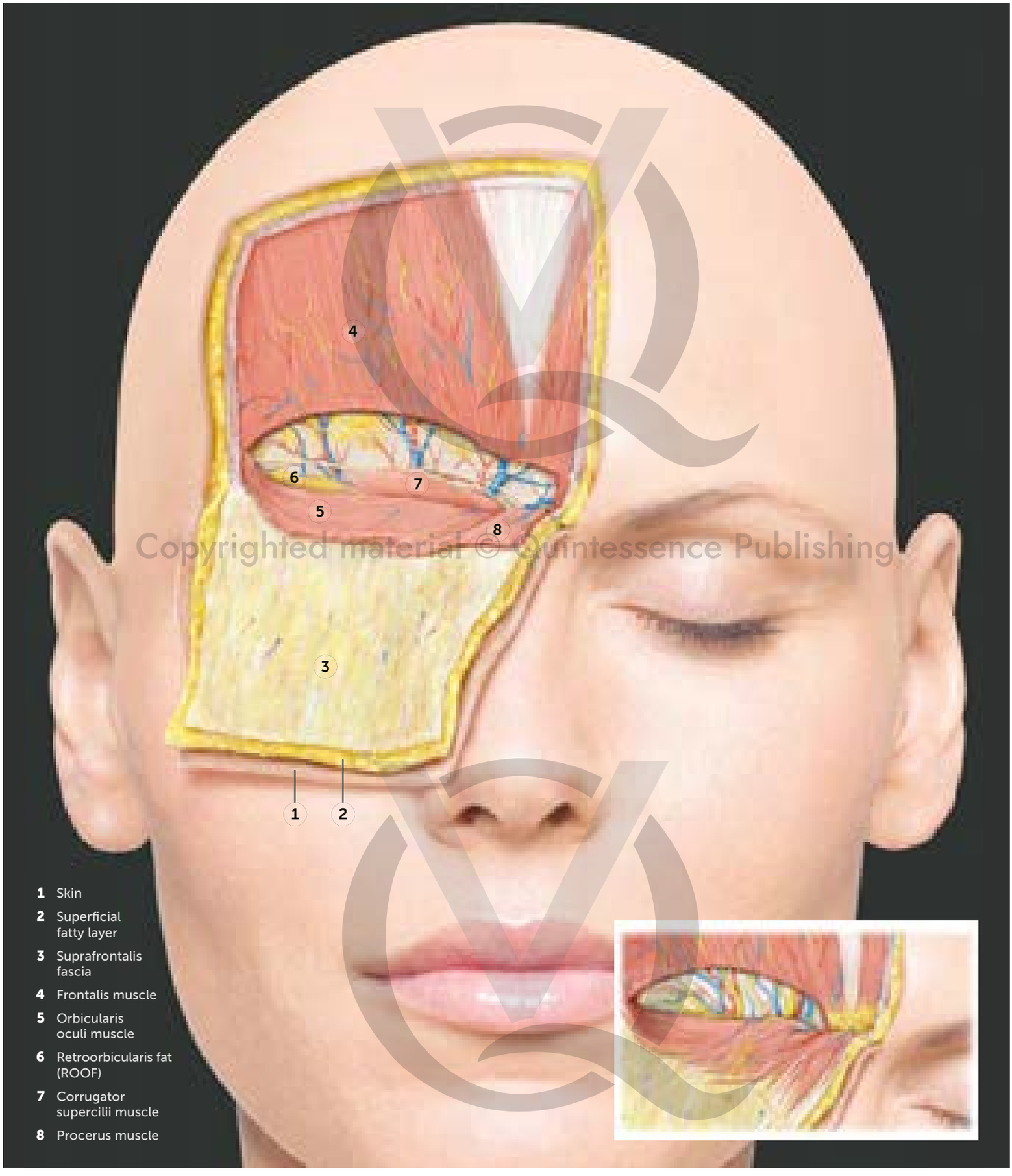

Copyrighted material © Quintessence Publishing

8 Reflection of the skin, superficial fatty layer, suprafrontalis fascia, and the eyebrow depressor muscles. The retroorbicularis oculi fat (ROOF) is exposed. *Small image:* The ROOF and the retrofrontalis fatty layer have been removed to expose the main trunk of the supraorbital and supratrochlear neurovascular structures.

Copyrighted material © Quintessence Publishing

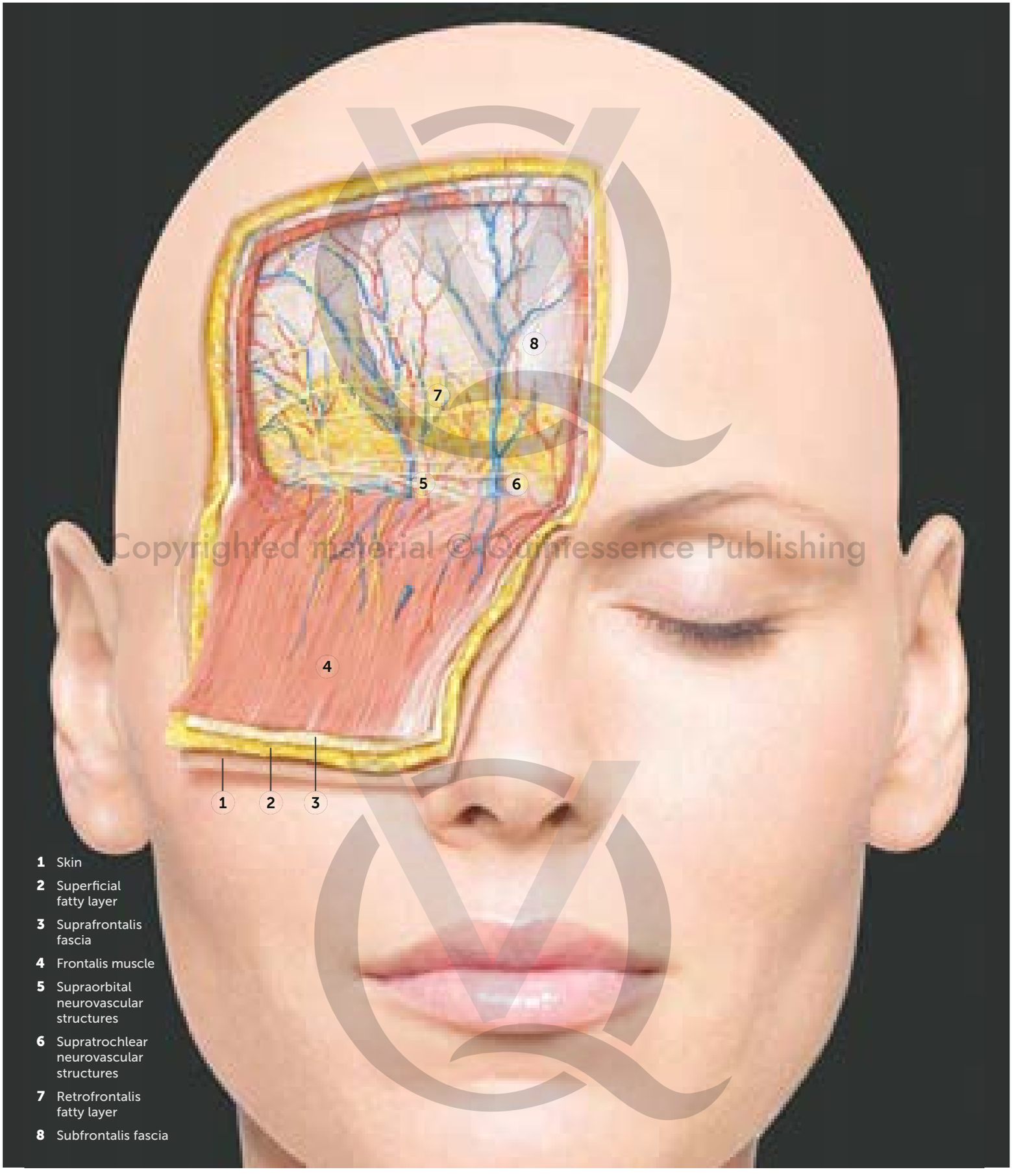

Copyrighted material © Quintessence Publishing

9 Reflection of the skin, superficial fatty layer, suprafrontalis fascia, and frontalis muscle. The retrofrontalis fatty layer is exposed, showing the pathway of the supraorbital and supratrochlear neurovascular structures as they travel superficial to the subfrontalis fascia.

Copyrighted material © Quintessence Publishing



Copyrighted material © Quintessence Publishing



Copyrighted material © Quintessence Publishing

Chapter 5

Infraorbital

Copyrighted material © Quintessence Publishing

Copyrighted material © Quintessence Publishing

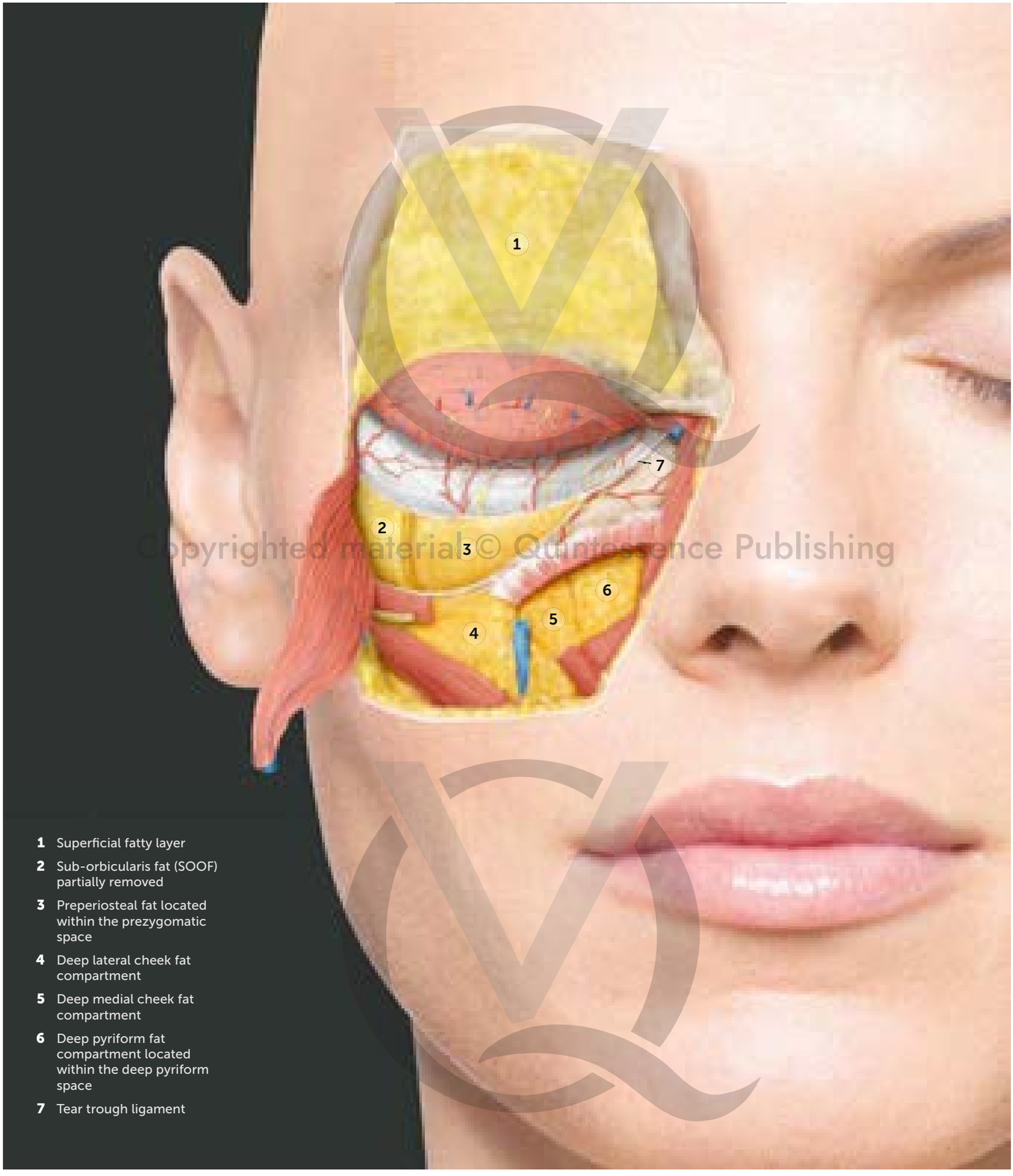

1 Superficial fatty layer
2 Sub-orbicularis fat (SOOF) partially removed
3 Preperiosteal fat located within the prezygomatic space
4 Deep lateral cheek fat compartment
5 Deep medial cheek fat compartment
6 Deep pyriform fat compartment located within the deep pyriform space
7 Tear trough ligament

Copyrighted material © Quintessence Publishing

9 Reflection of the skin, the superficial fatty layer, the orbicularis oculi muscle, the SOOF, and transsecting the zygomaticus minor and the levator labii superioris muscles, exposing the deep medial cheek fat compartment and the deep pyriform space.

Copyrighted material © Quintessence Publishing

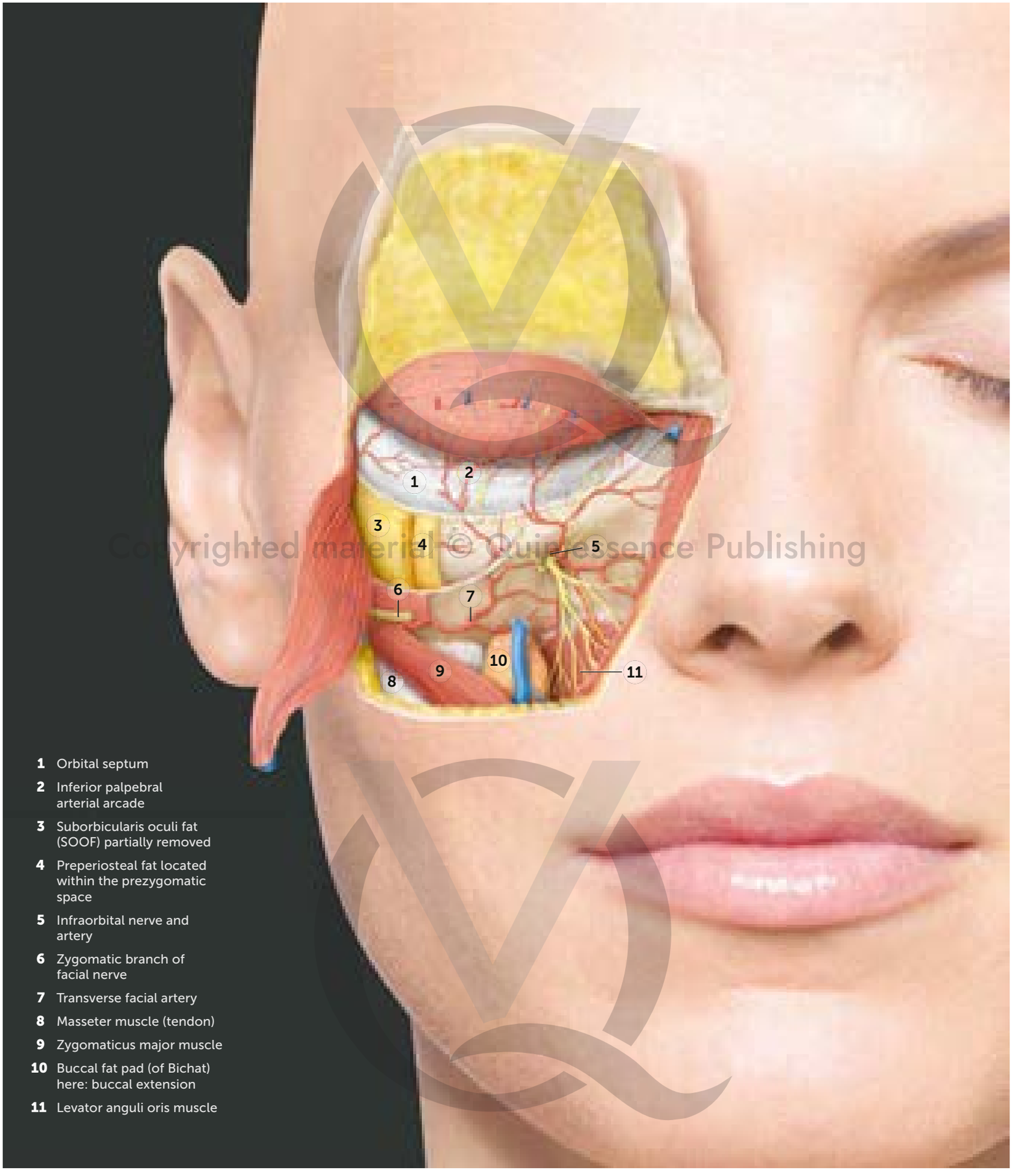

1 Orbital septum
2 Inferior palpebral arterial arcade
3 Suborbicularis oculi fat (SOOF) partially removed
4 Preperiosteal fat located within the prezygomatic space
5 Infraorbital nerve and artery
6 Zygomatic branch of facial nerve
7 Transverse facial artery
8 Masseter muscle (tendon)
9 Zygomaticus major muscle
10 Buccal fat pad (of Bichat) here: buccal extension
11 Levator anguli oris muscle

Copyrighted material © Quintessence Publishing

10 Reflection of the skin, the superficial fatty layer, the orbicularis oculi muscle, the levator labii superioris muscle, and all deep midfacial fat compartments, exposing the infraorbital neurovascular structures.

Copyrighted material © Quintessence Publishing



Copyrighted material © Quintessence Publishing



Copyrighted material © Quintessence Publishing

Chapter 12

Neck

Copyrighted material © Quintessence Publishing

Copyrighted material © Quintessence Publishing

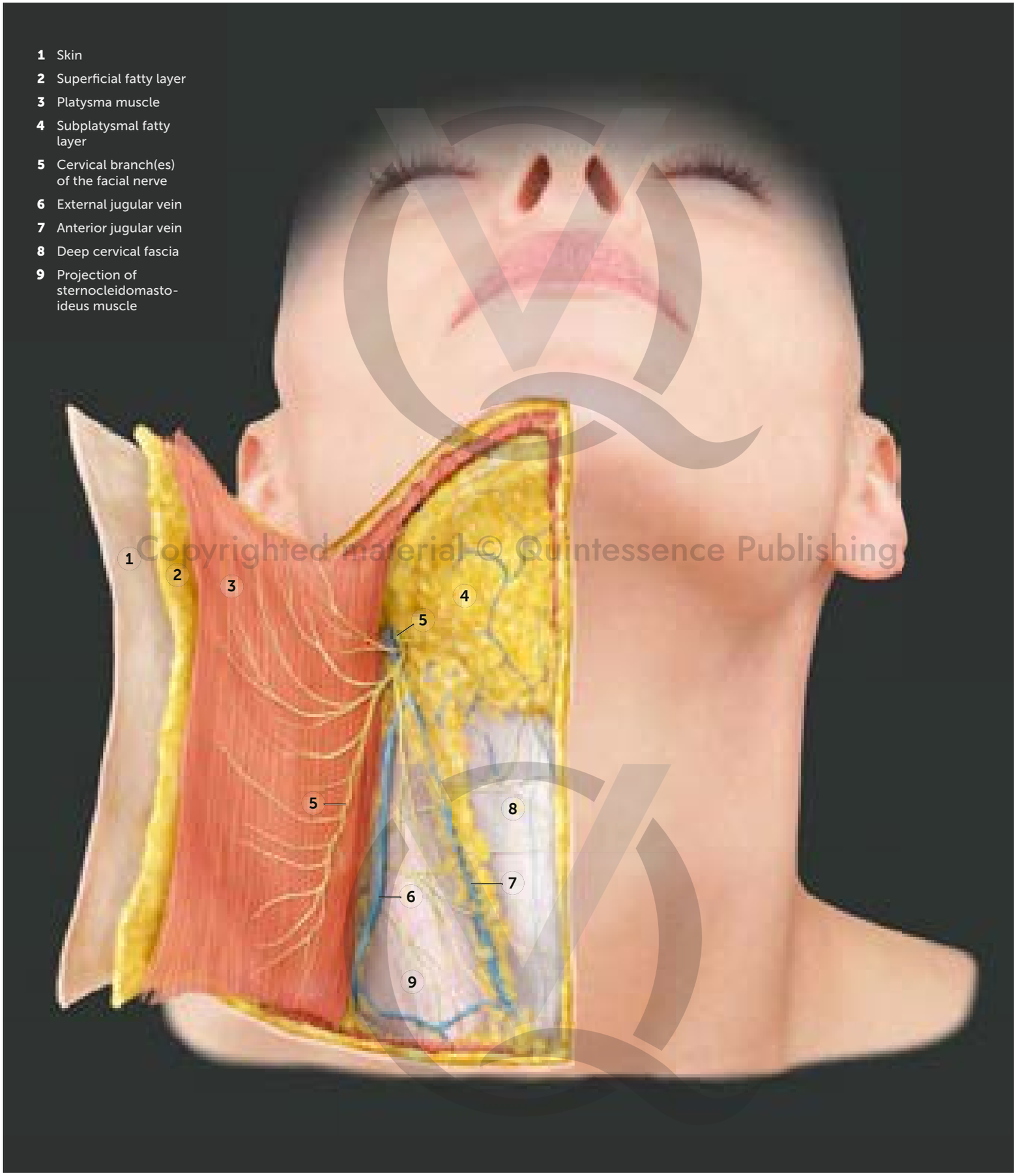

Copyrighted material © Quintessence Publishing

5 Reflection of the skin, the superficial fatty layer, and of the platysma muscle, exposing the subplatysmal fatty layer.

Copyrighted material © Quintessence Publishing

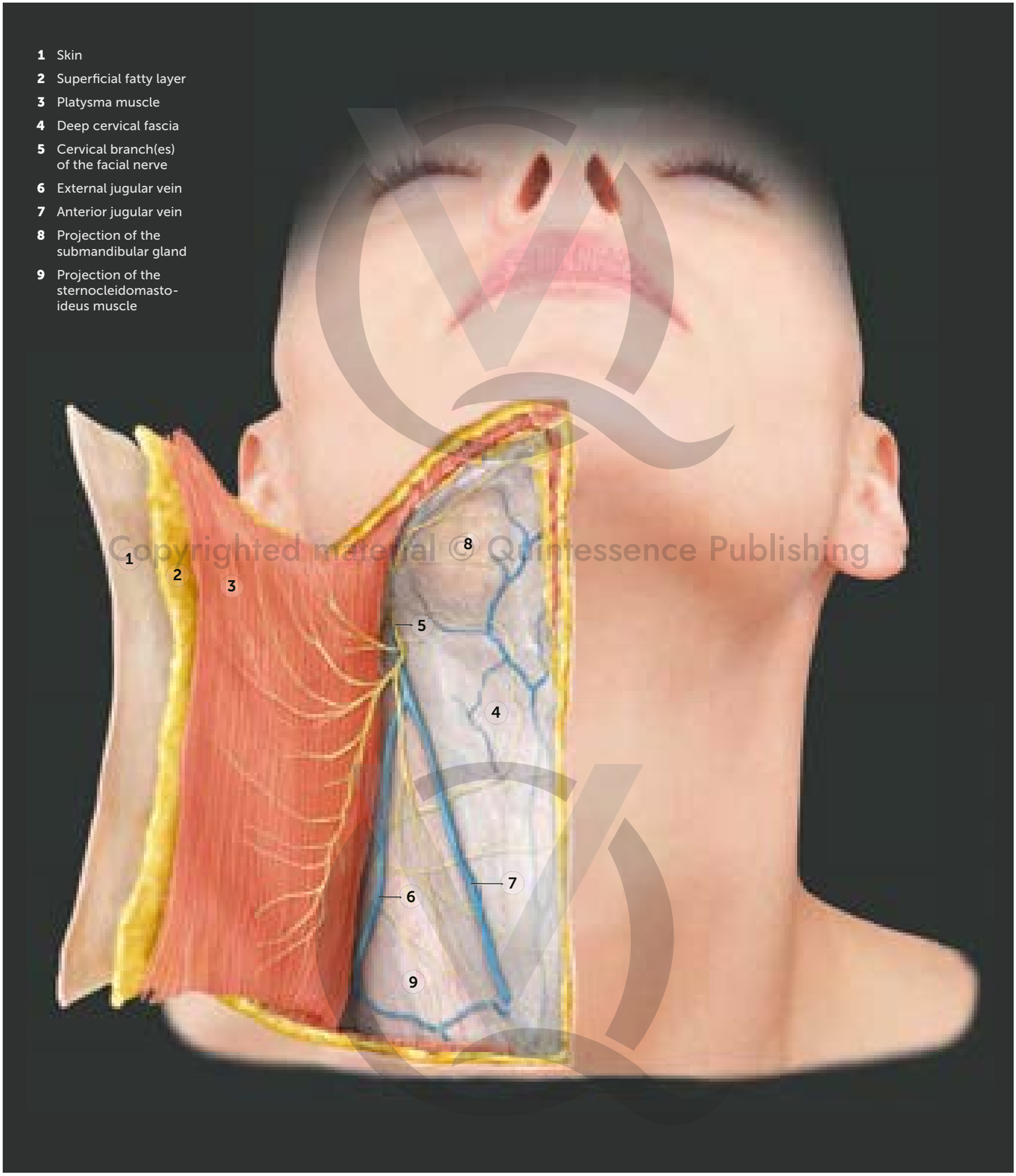

Copyrighted material © Quintessence Publishing

6 Reflection of the skin, the superficial fatty layer, the platysma muscle, and removal of the subplatysmal fatty layer, exposing the deep cervical fascia.

Copyrighted material © Quintessence Publishing



Copyrighted material © Quintessence Publishing



Copyrighted material © Quintessence Publishing

Chapter 13

Overview

Copyrighted material © Quintessence Publishing

Copyrighted material © Quintessence Publishing

Overview: Anatomic systems of the face

The face is composed of a bony platform which includes the various facial bones. The overlying soft tissues are connected to the bony platform via facial ligaments which expand in some cases all the way to the dermal undersurface. Additionally, facial ligaments are incorporated into a 3-dimensional connective tissue system which includes facial muscles, provides guidance and protection for facial nerves, arteries and veins. This specific 3-dimensional fascial system allows also for the force transmission between muscles and skin which at the dermal undersurface is termed retinacula cutis.

In the following each anatomic system (bones, ligaments, fat, muscles, arteries, veins and nerves) is depicted individually despite all of them need to be viewed as an interlacing biomechanical and aesthetic concept.

Copyrighted material © Quintessence Publishing

Copyrighted material © Quintessence Publishing



Copyrighted material © Quintessence Publishing



Copyrighted material © Quintessence Publishing

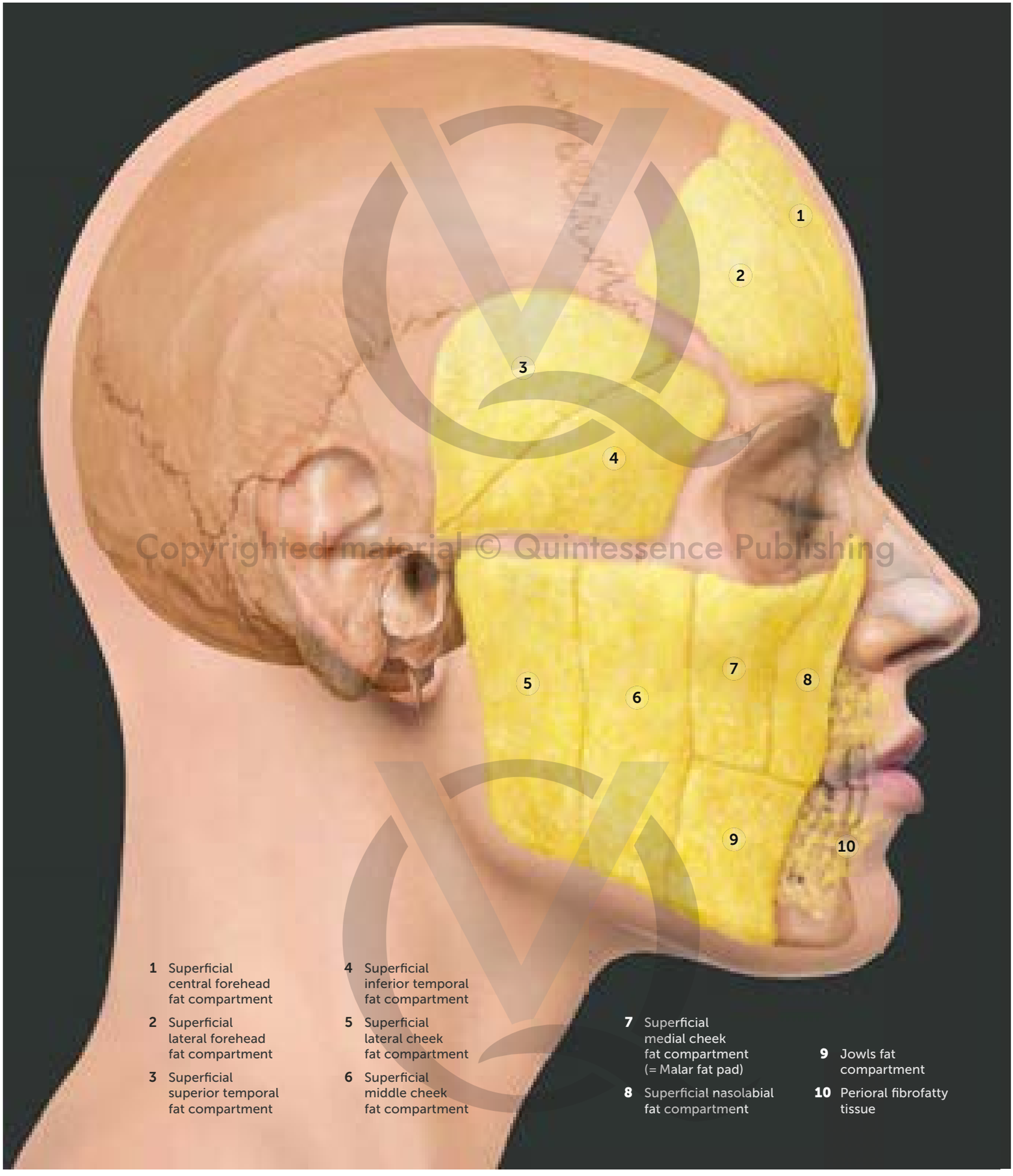

Copyrighted material © Quintessence Publishing

5 Superficial fat compartments of the face (lateral view).

Copyrighted material © Quintessence Publishing

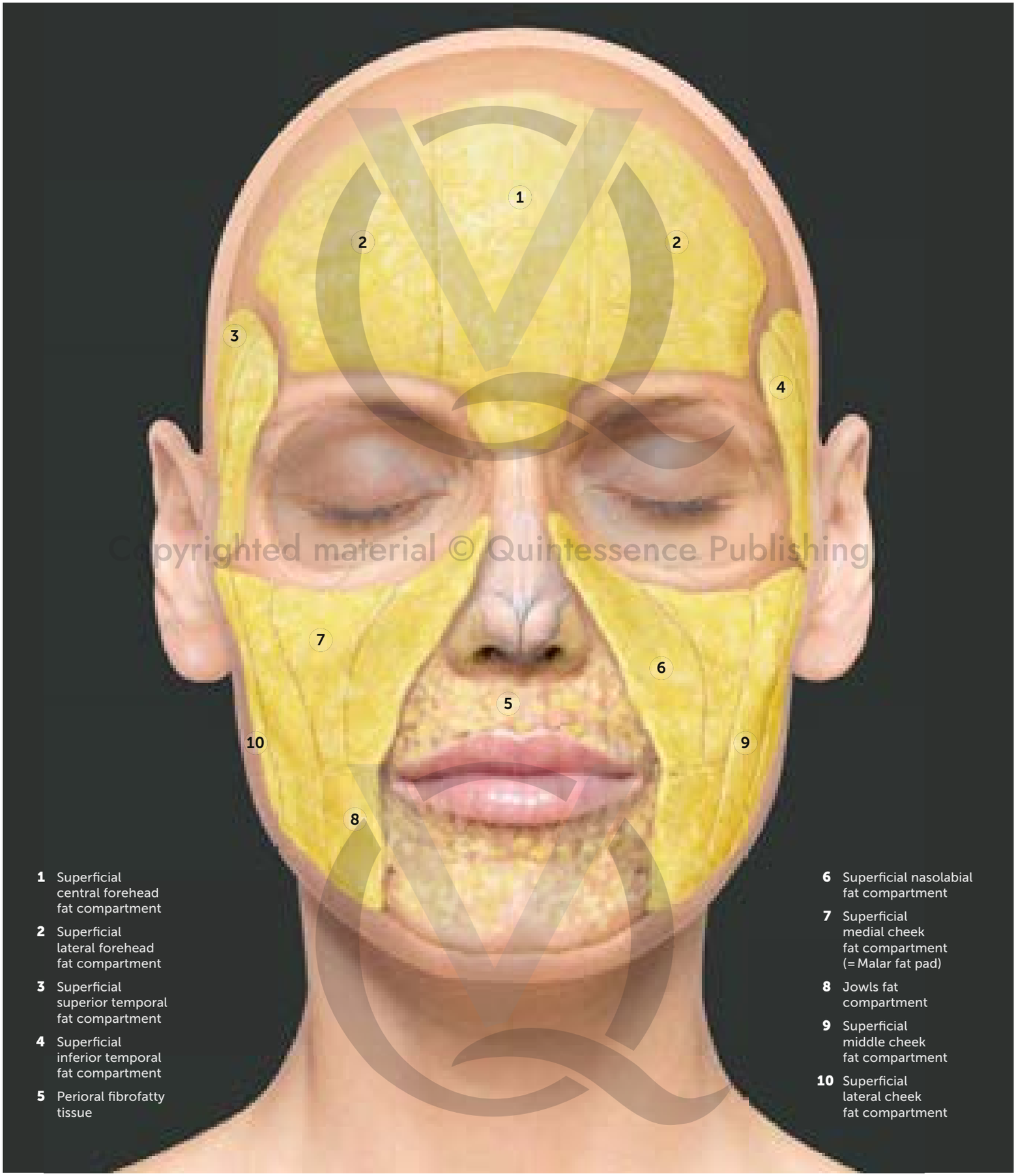

Copyrighted material © Quintessence Publishing

6 Superficial fat compartments of the face (frontal view).

Copyrighted material © Quintessence Publishing

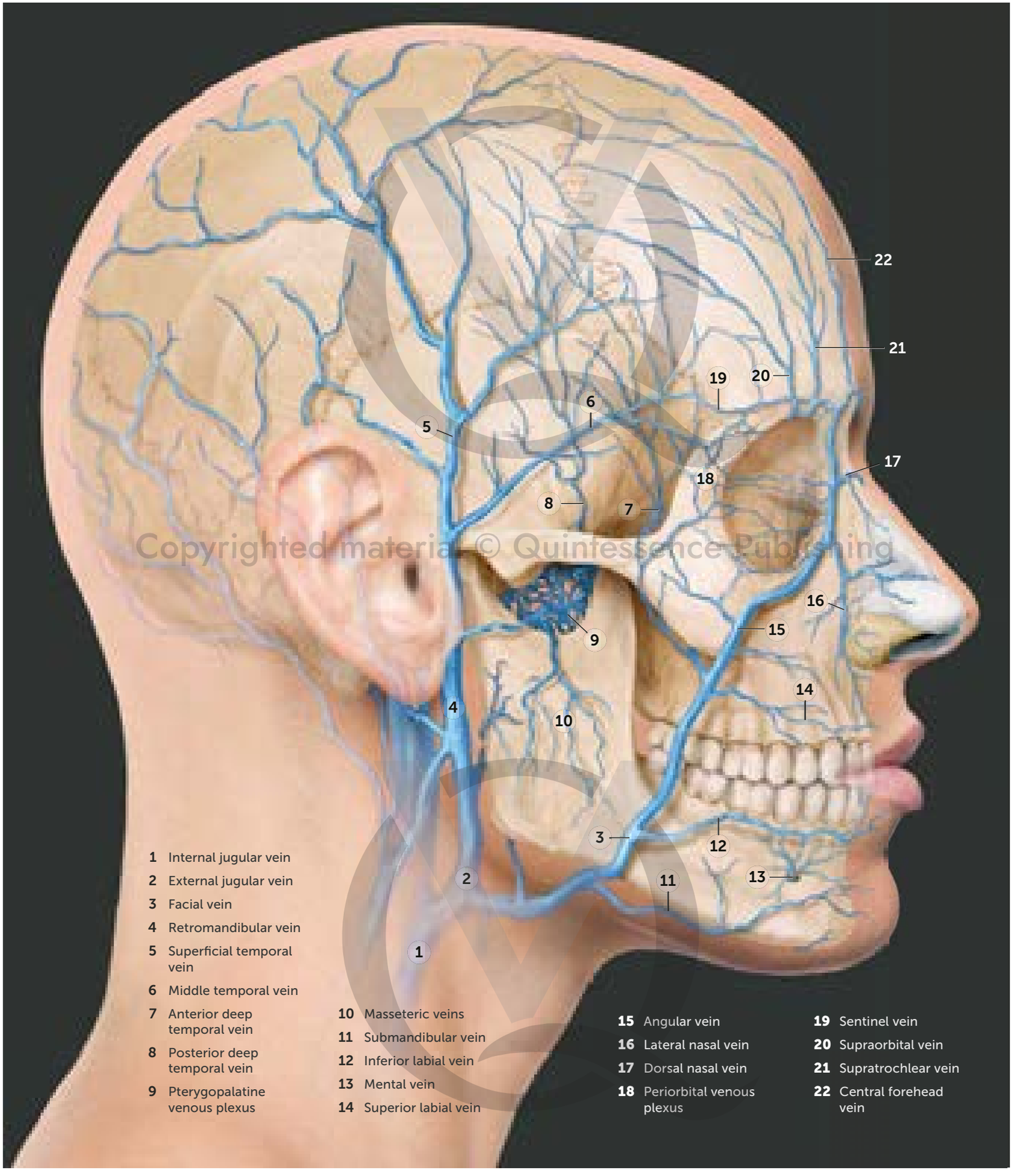

Copyrighted material © Quintessence Publishing

13 Veins of the face (lateral view).

Copyrighted material © Quintessence Publishing

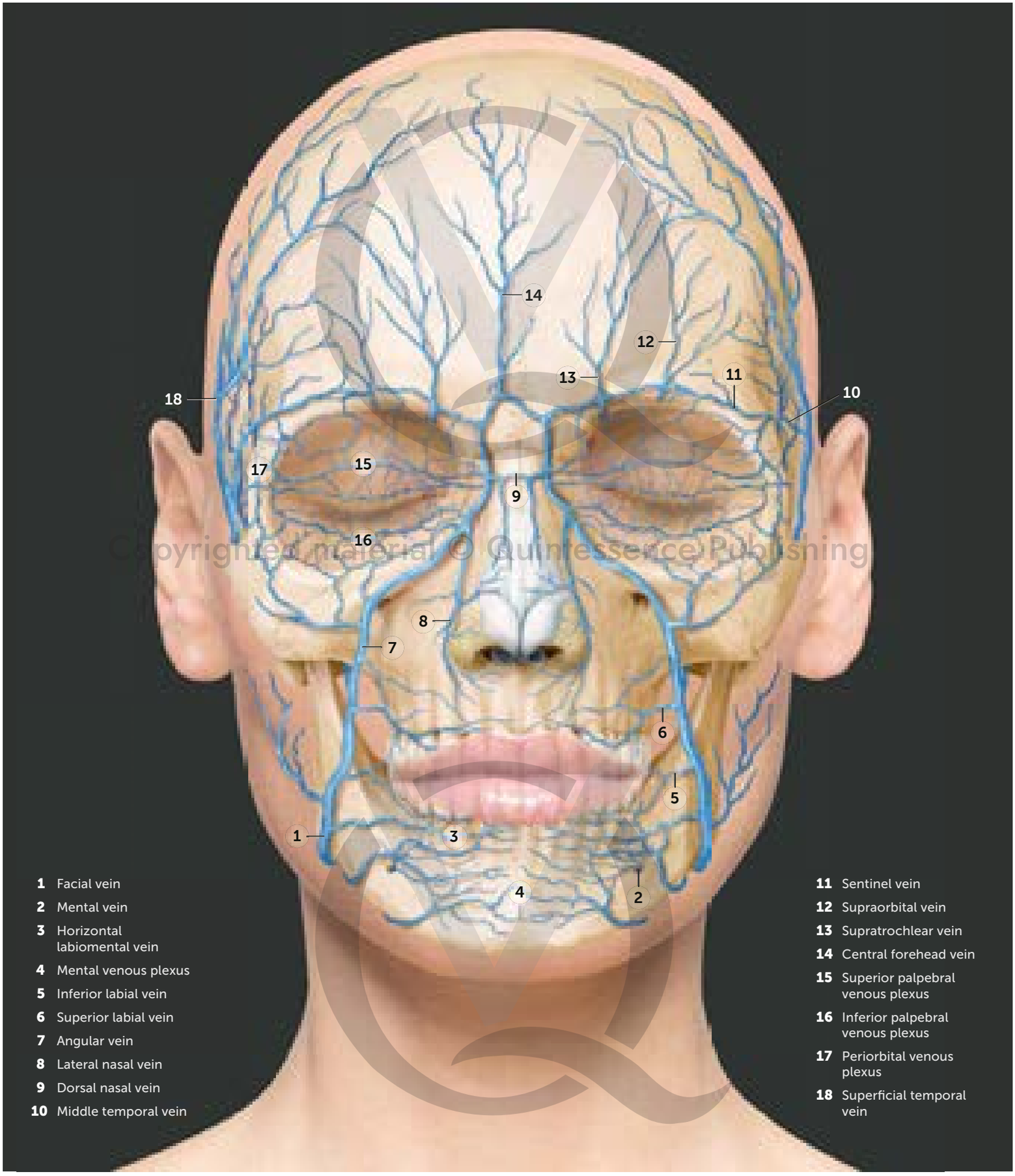

1 Facial vein
2 Mental vein
3 Horizontal labiomental vein
4 Mental venous plexus
5 Inferior labial vein
6 Superior labial vein
7 Angular vein
8 Lateral nasal vein
9 Dorsal nasal vein
10 Middle temporal vein
11 Sentinel vein
12 Supraorbital vein
13 Supratrochlear vein
14 Central forehead vein
15 Superior palpebral venous plexus
16 Inferior palpebral venous plexus
17 Periorbital venous plexus
18 Superficial temporal vein

Copyrighted material © Quintessence Publishing

14 Veins of the face (frontal view).

Copyrighted material © Quintessence Publishing